Dermatopathology Slide Review Part 35

Paul K. Shitabata, M.D.
Dermatopathology Institute

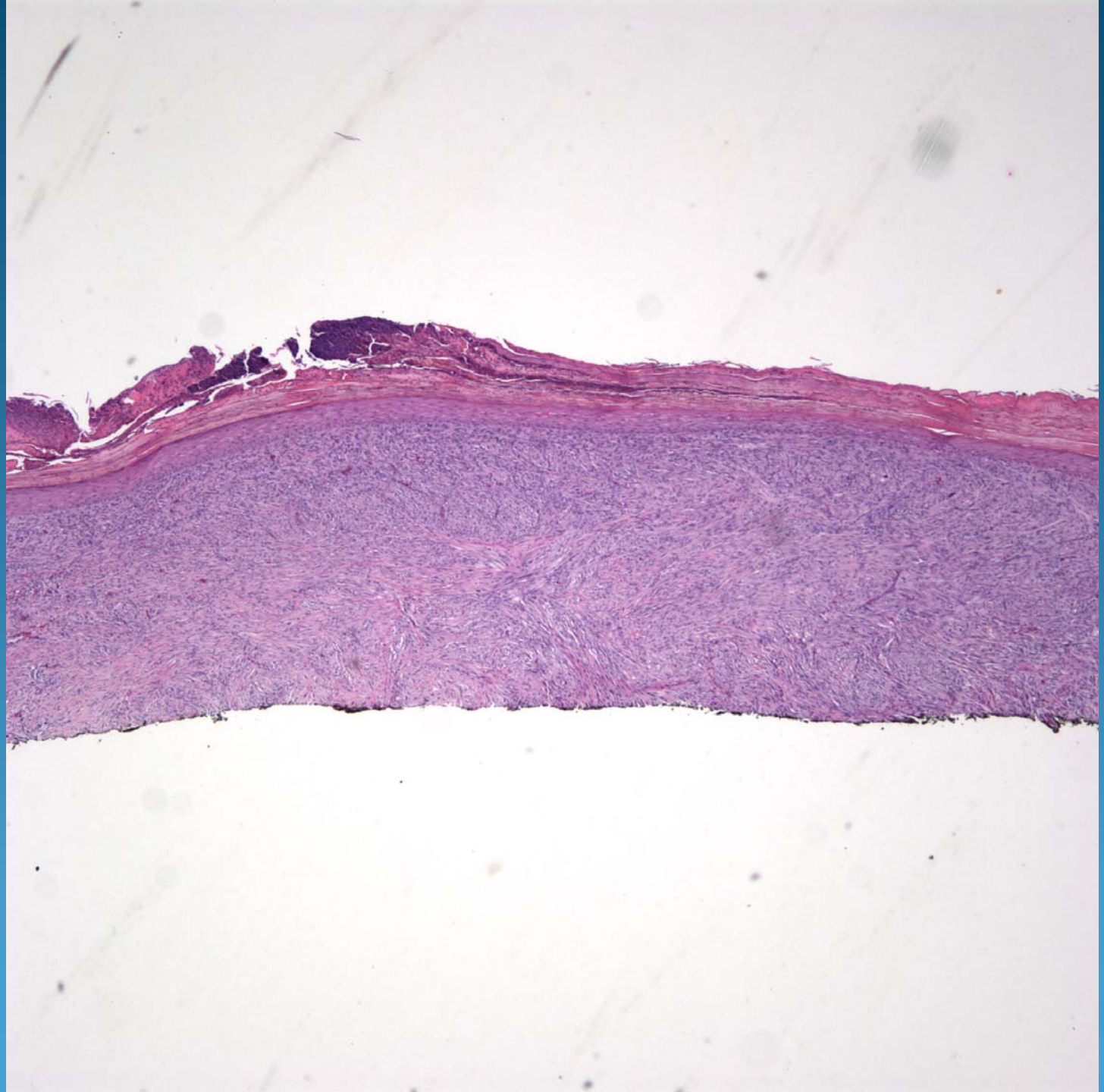

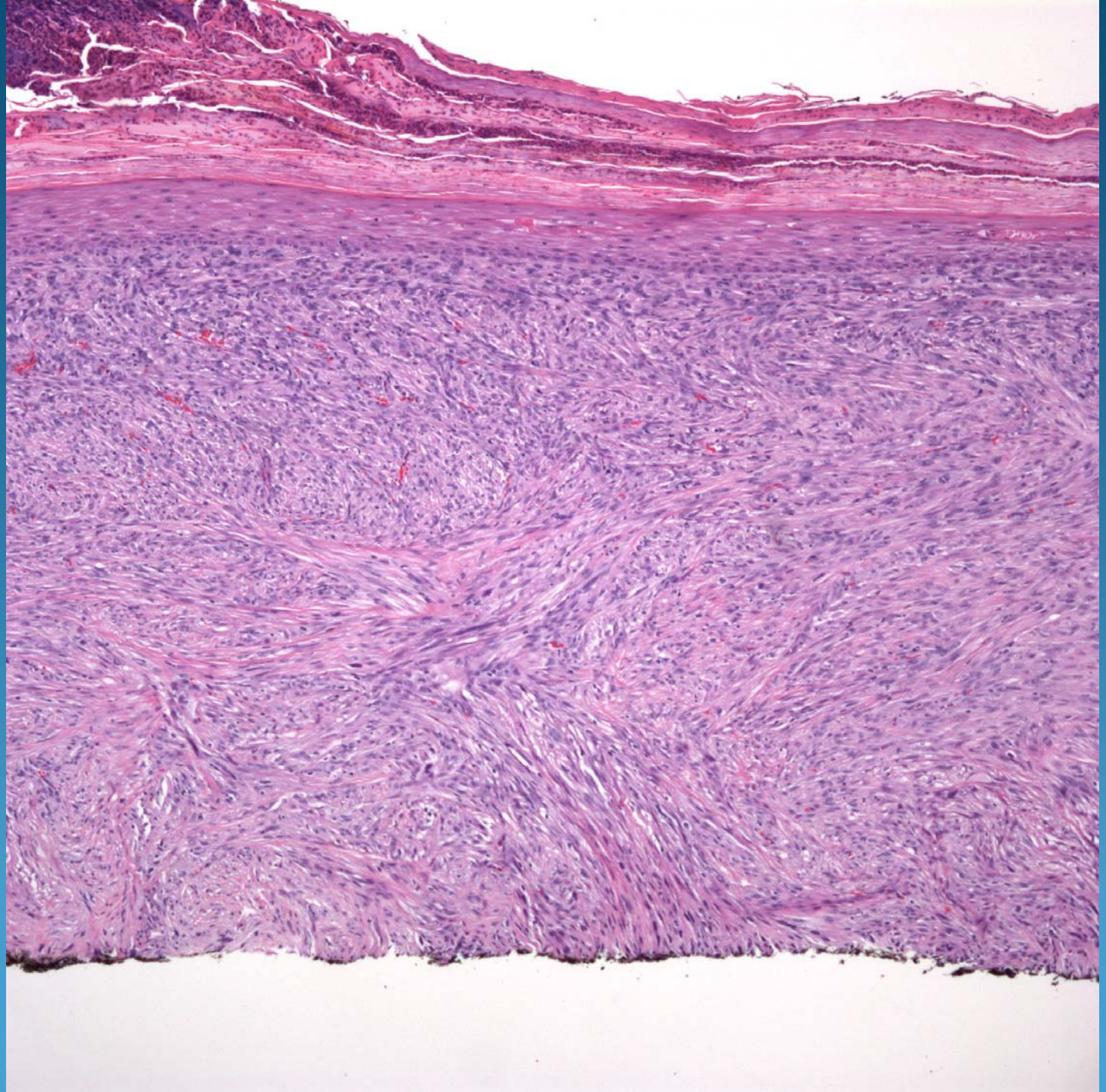

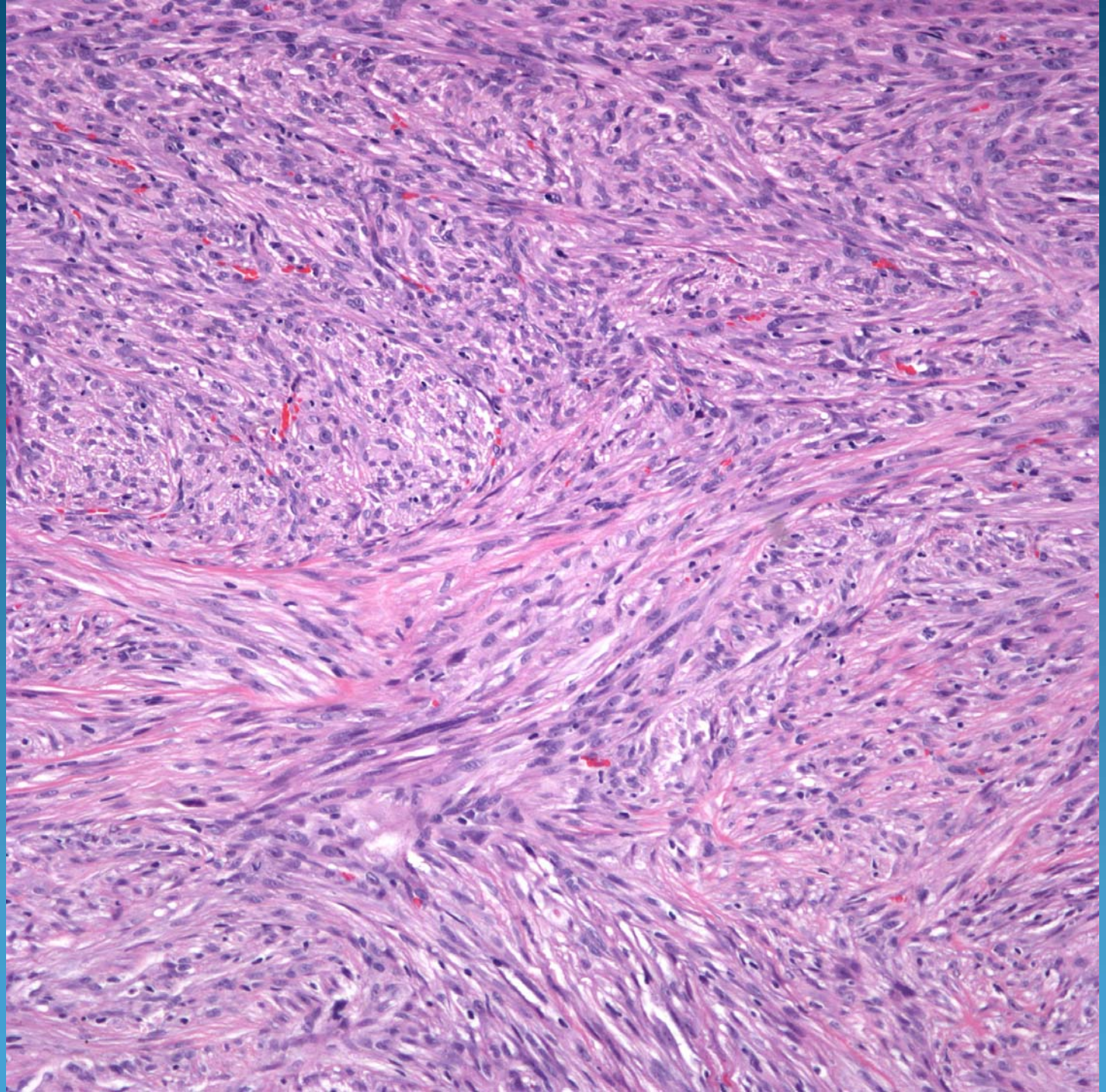

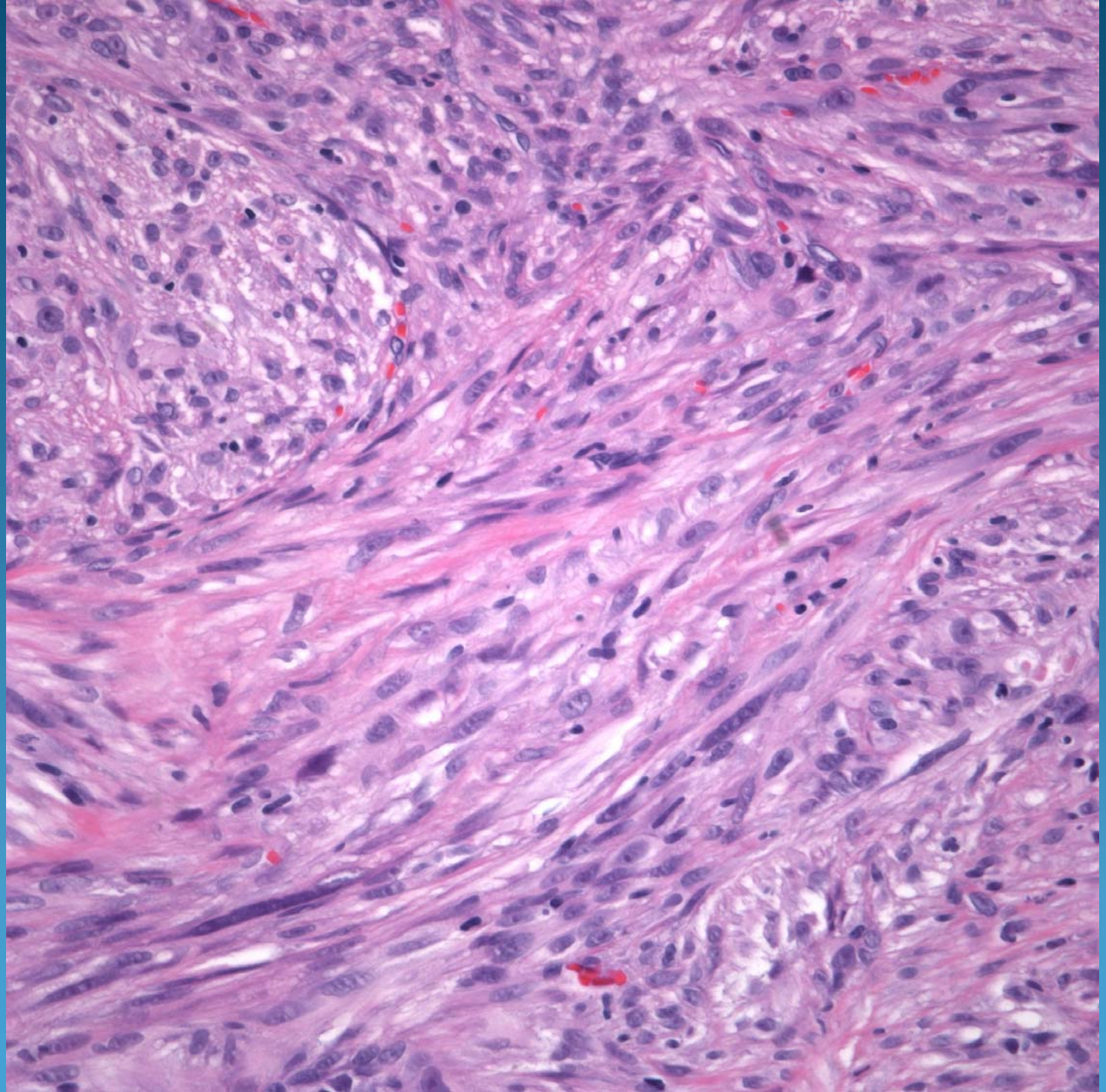

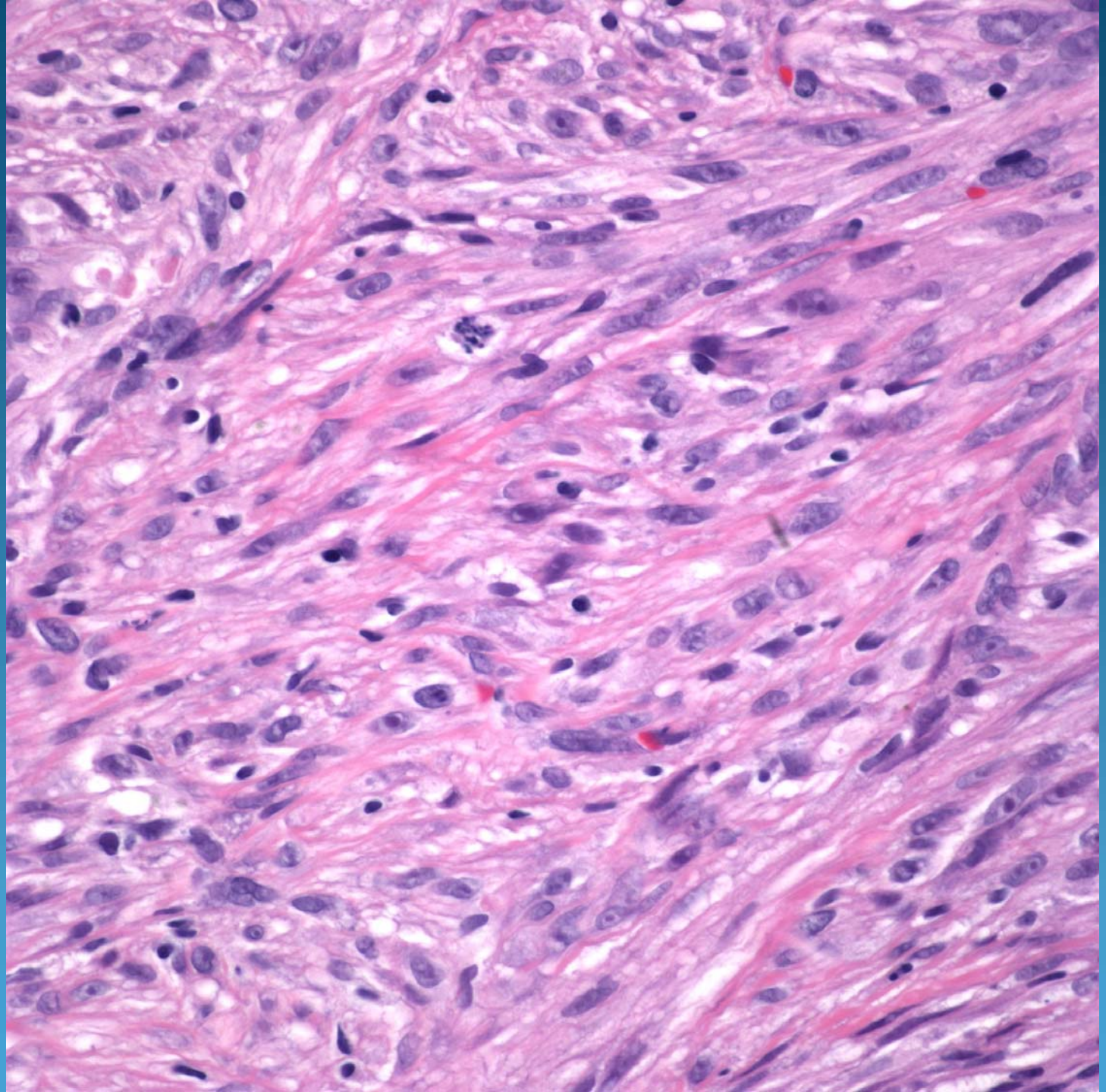

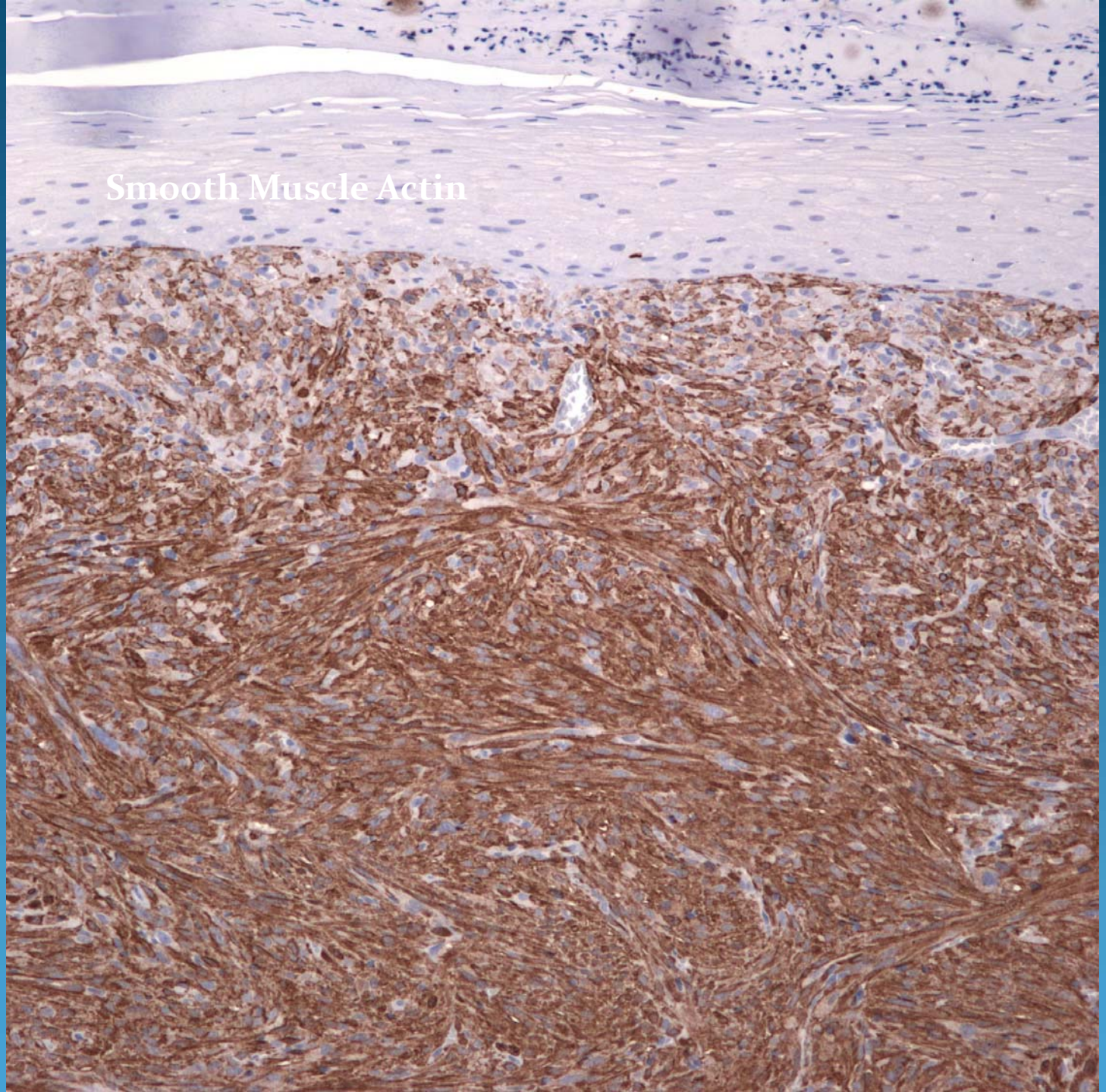
Smooth Muscle Actin

Cutaneous Leiomyosarcoma

Pearls

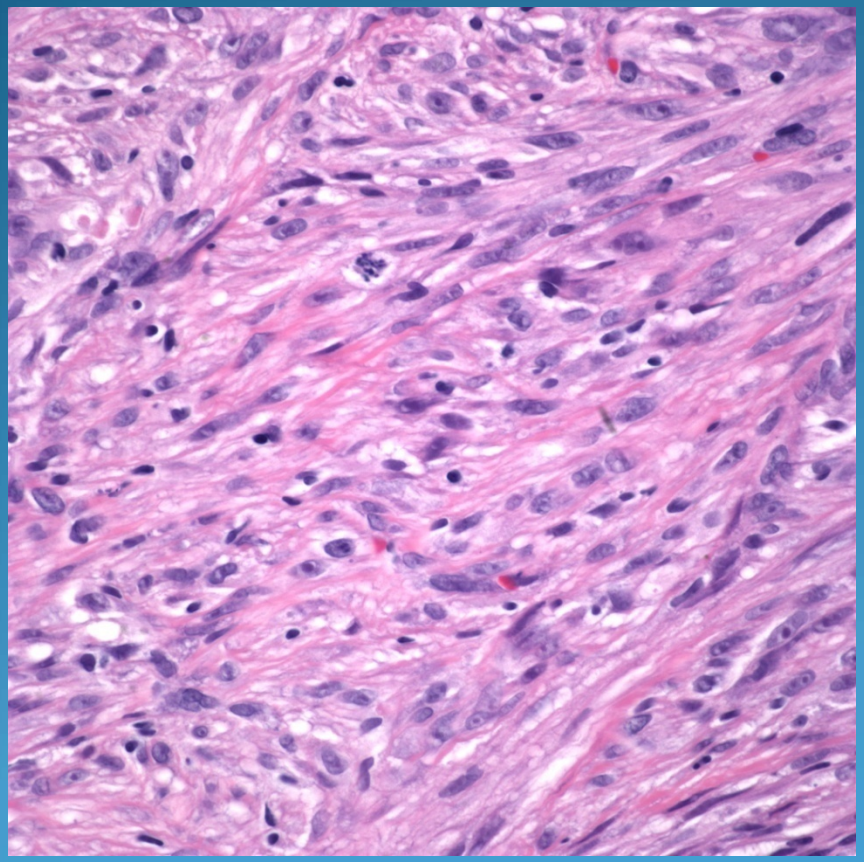

- Cytologically malignant spindle cell neoplasm
- May abut to overlying epidermis
- Intersecting fascicles with perinuclear clearing
- Increased mitotic figures
- DDX: AFX, Sarcomatoid carcinoma, melanoma, angiosarcoma
- Use IHC to confirm-SMA+

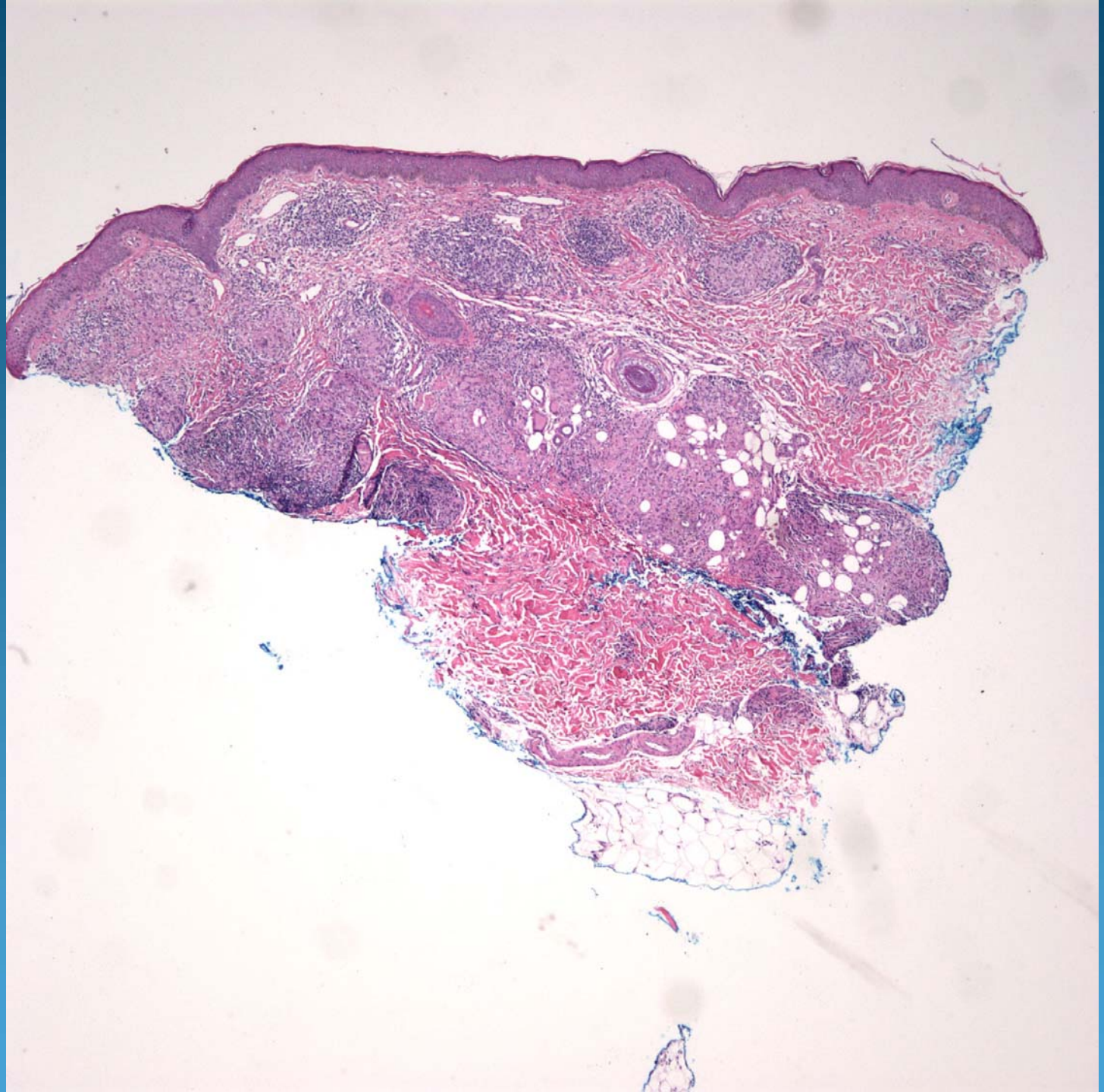

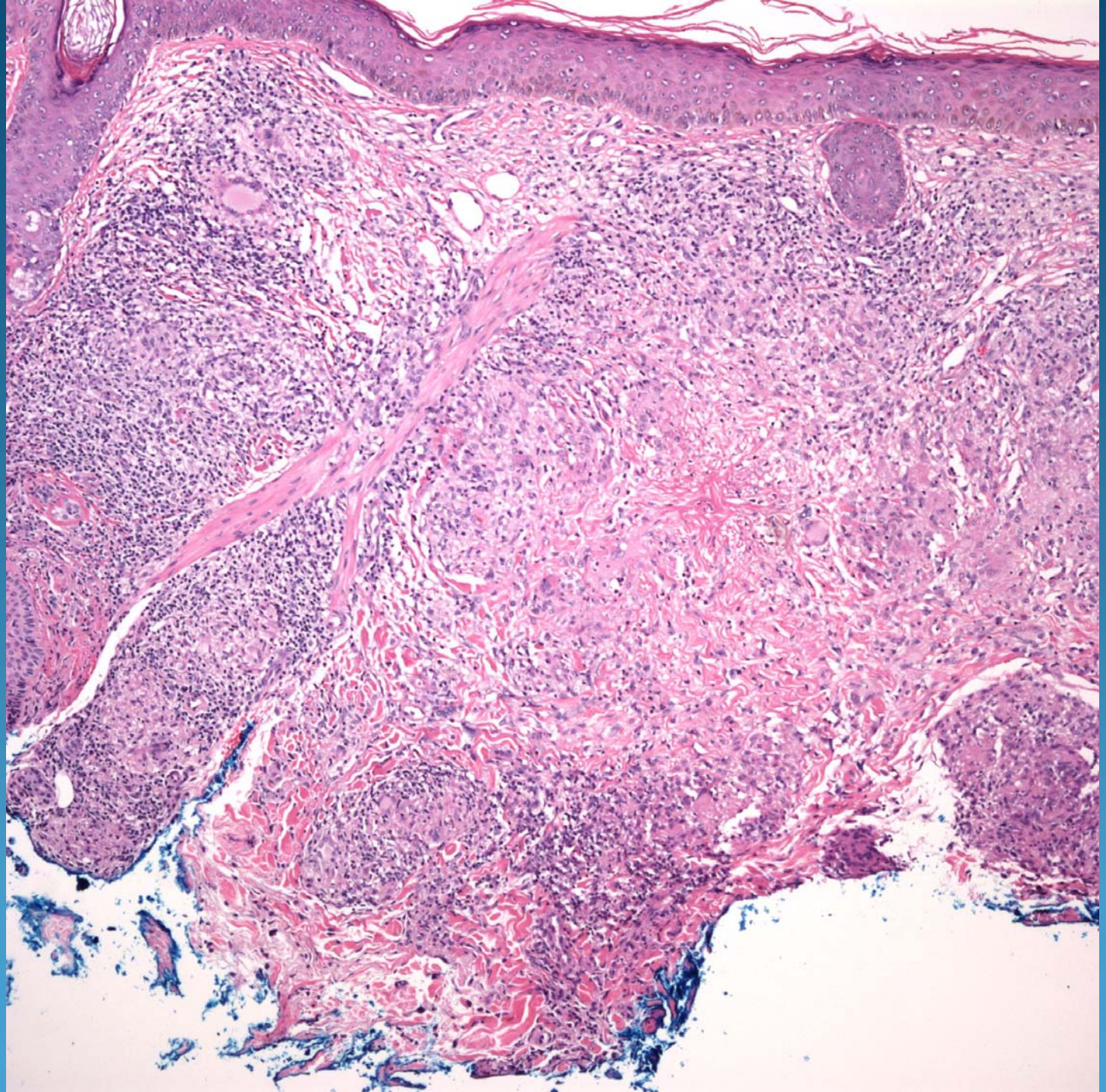

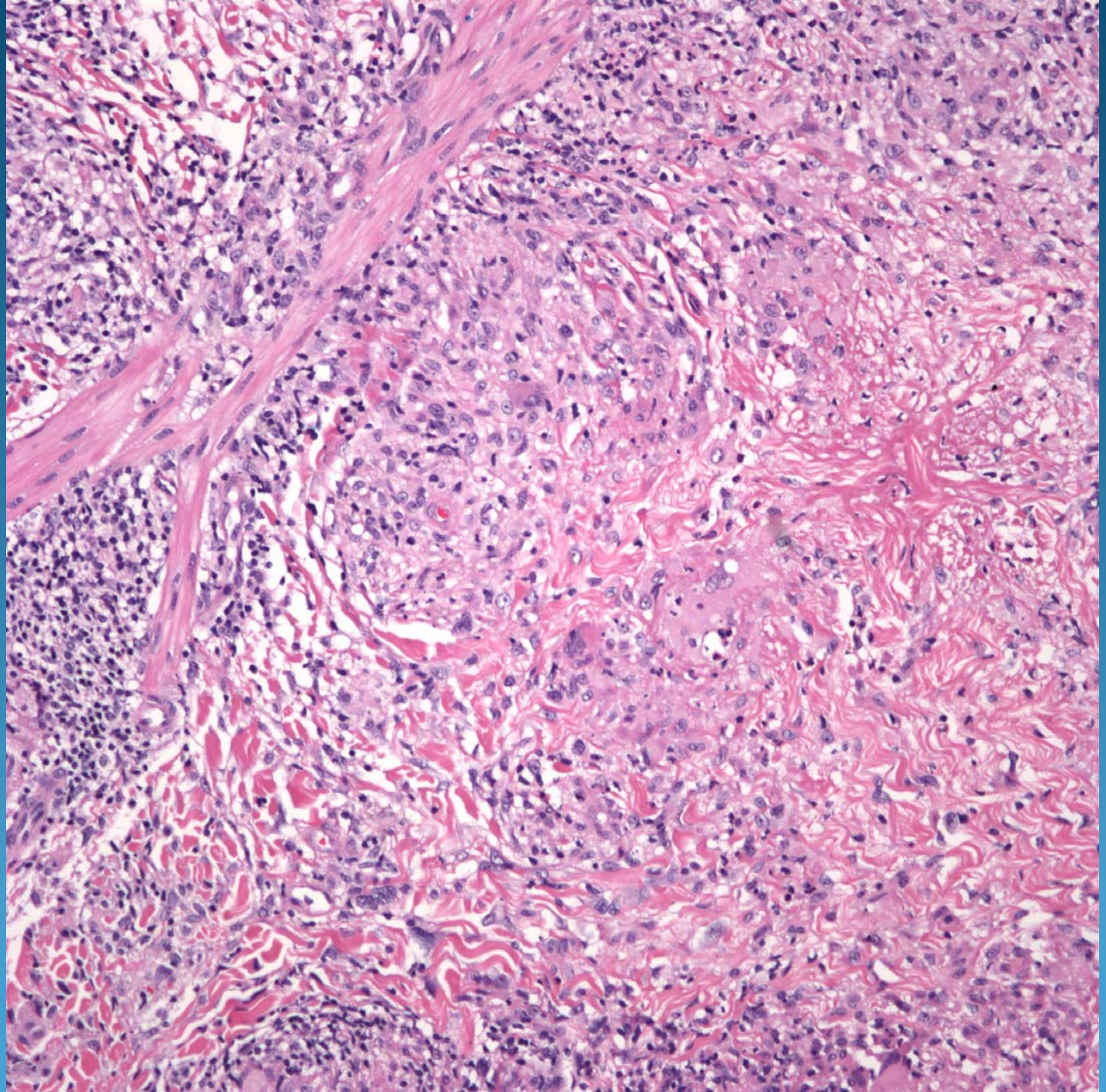

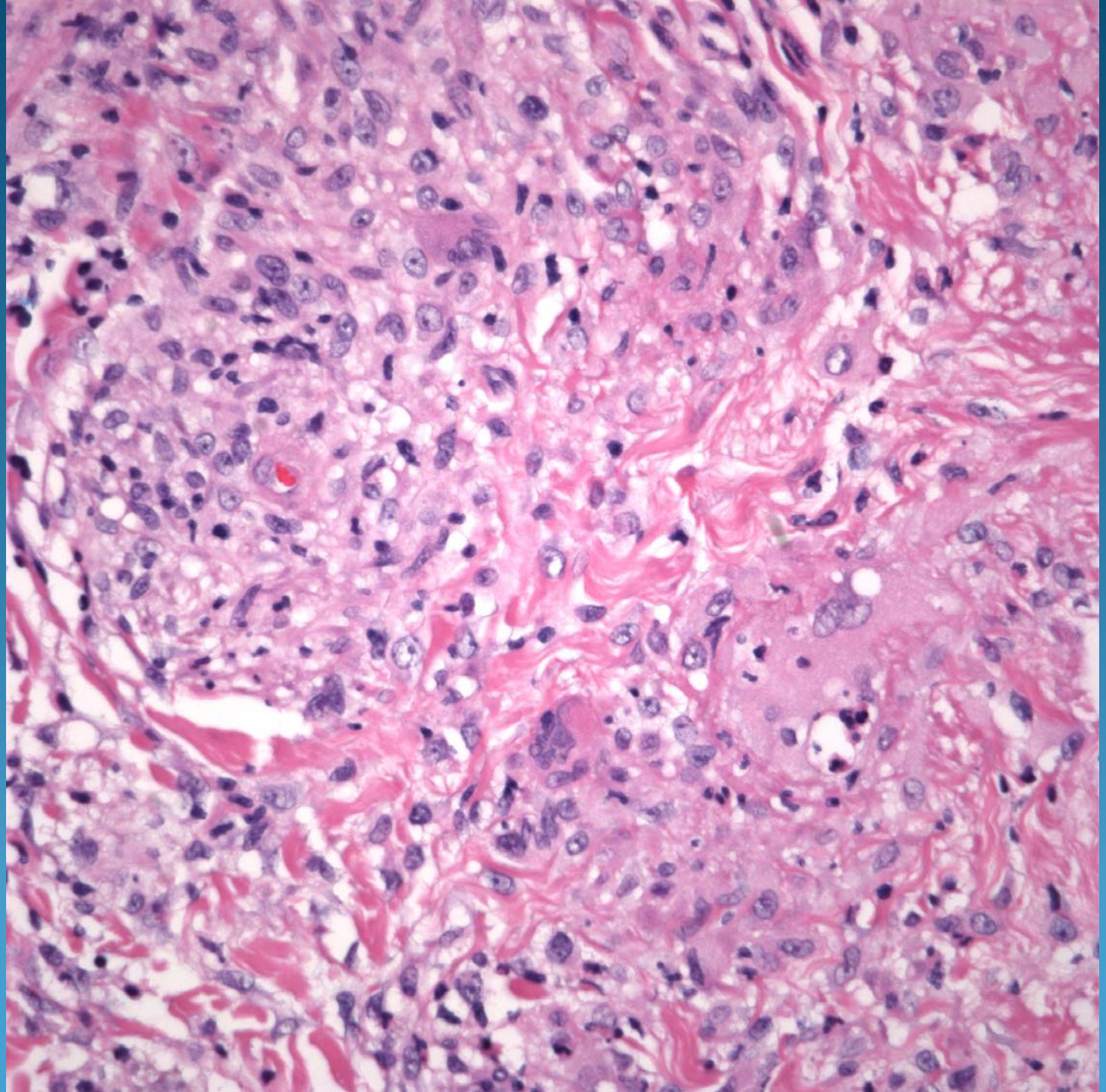

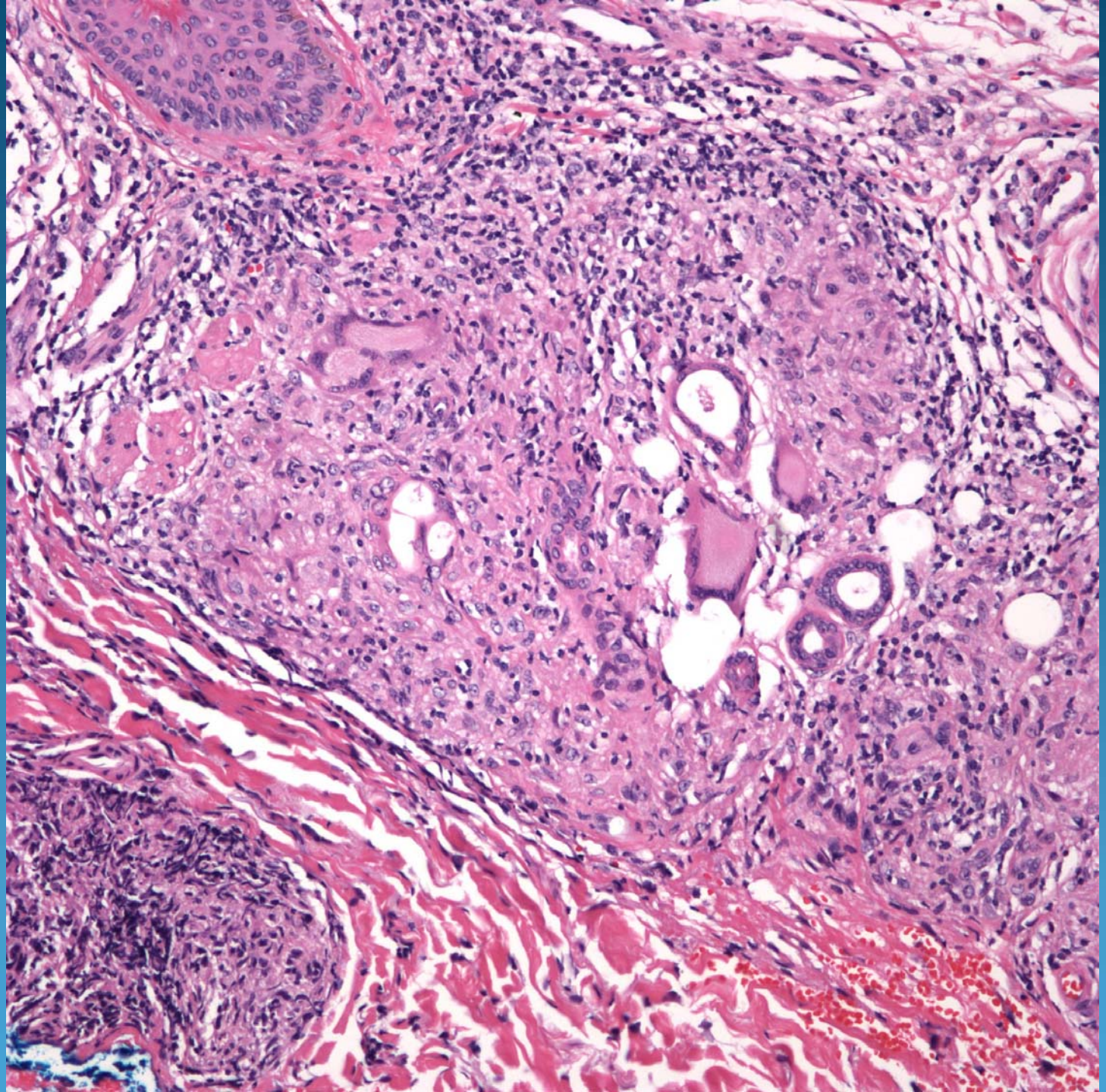

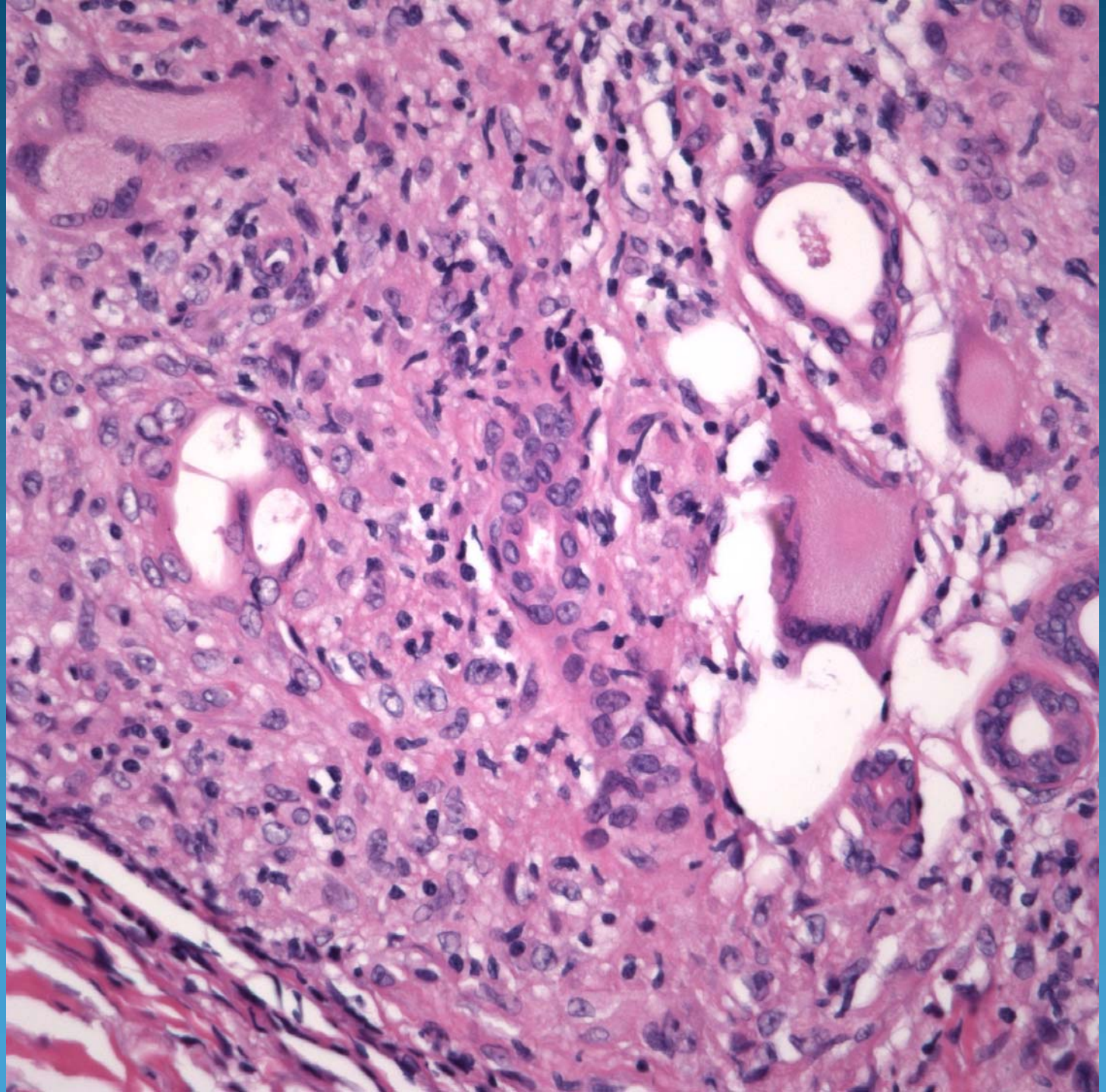

Lupus Vulgaris

Pearls

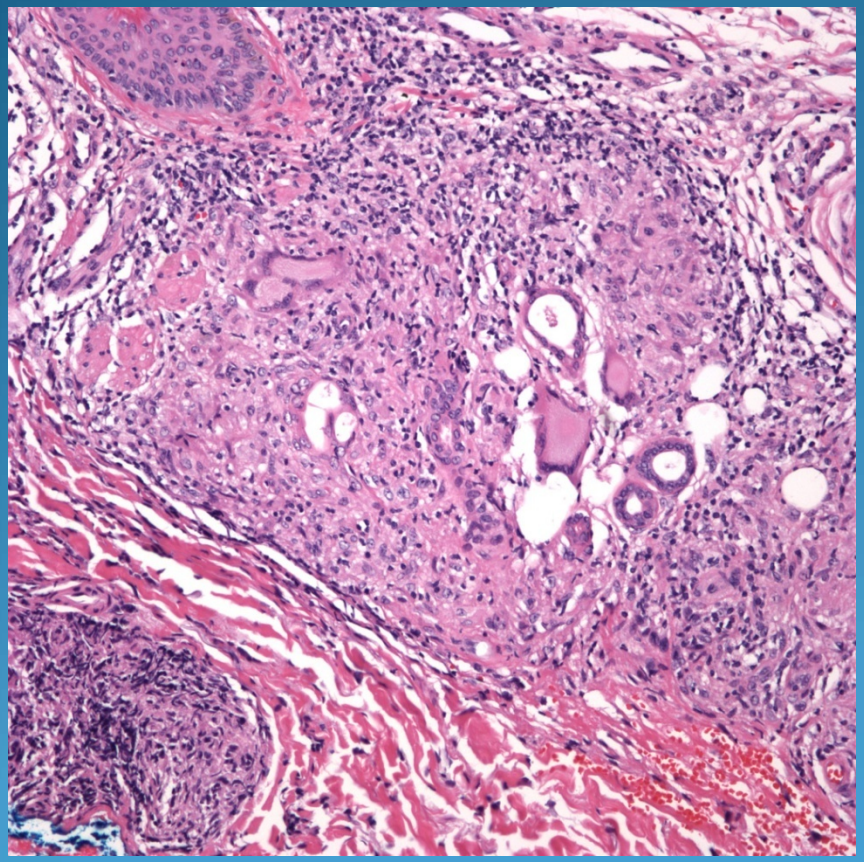

- Caseating granulomatous infiltrate with Langhans type giant cells
- AFB/Fite stains usually negative
- Complete with PAS stain
- Clinical hx of Mycobacterial infection

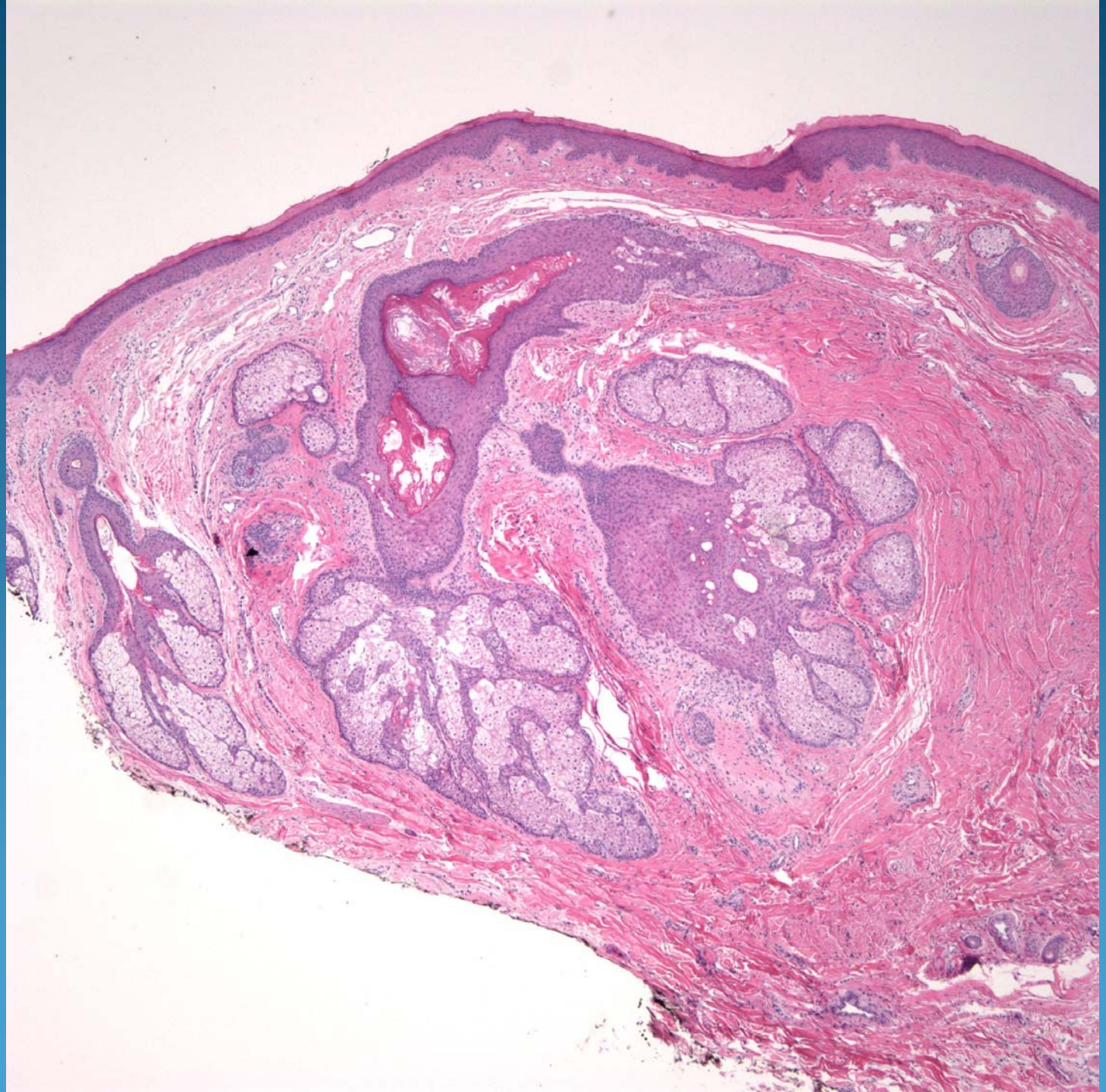

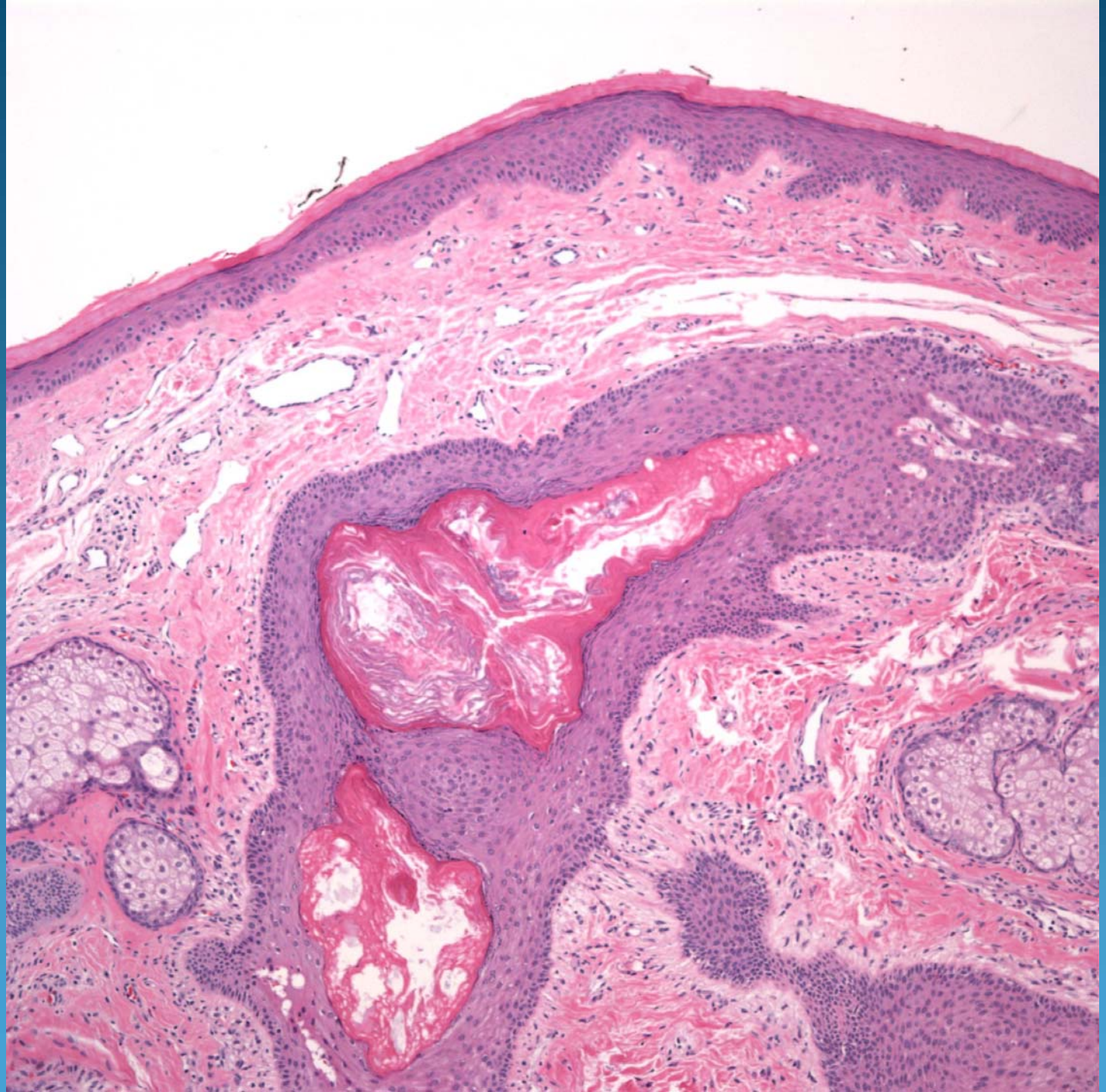

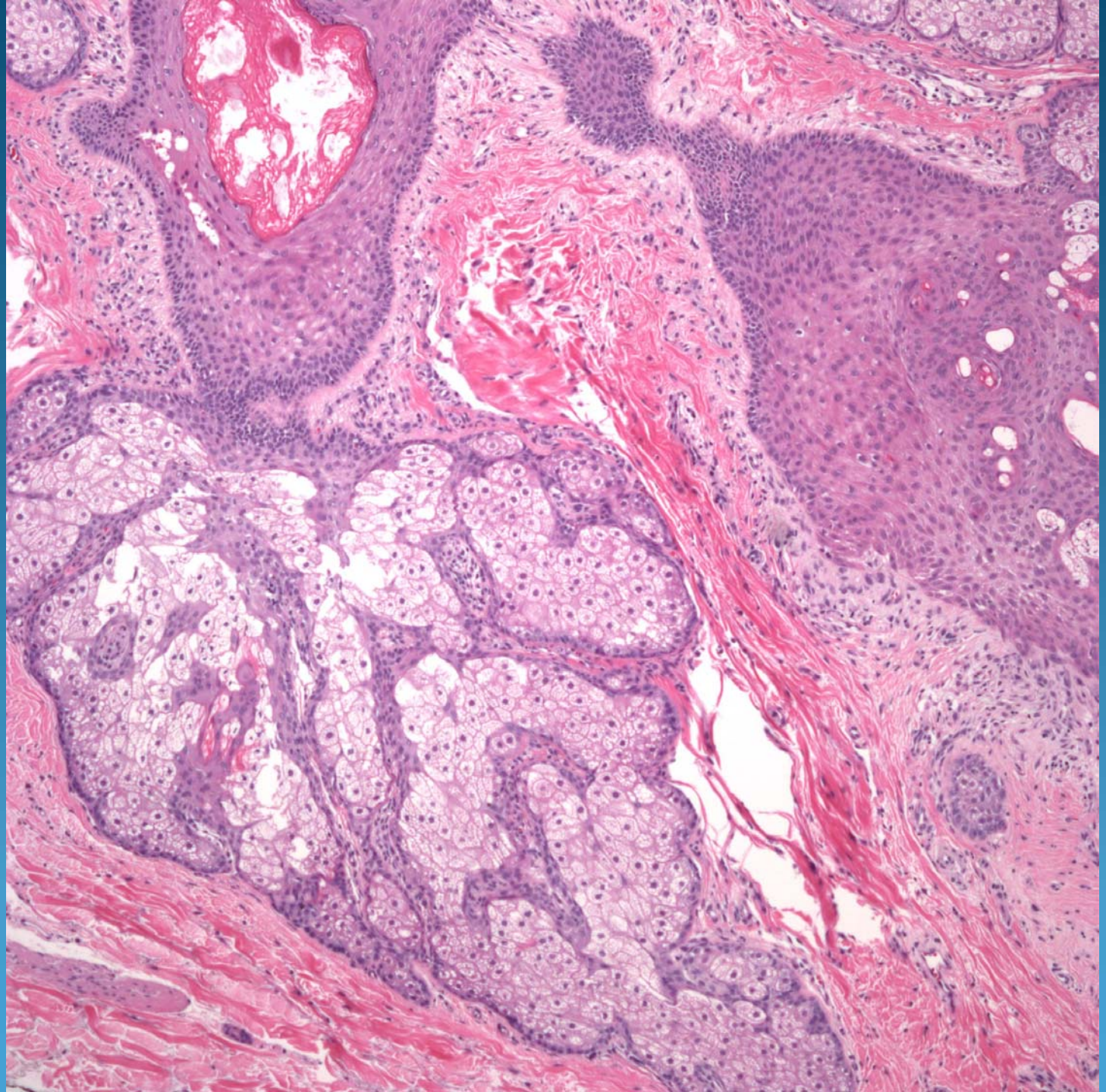

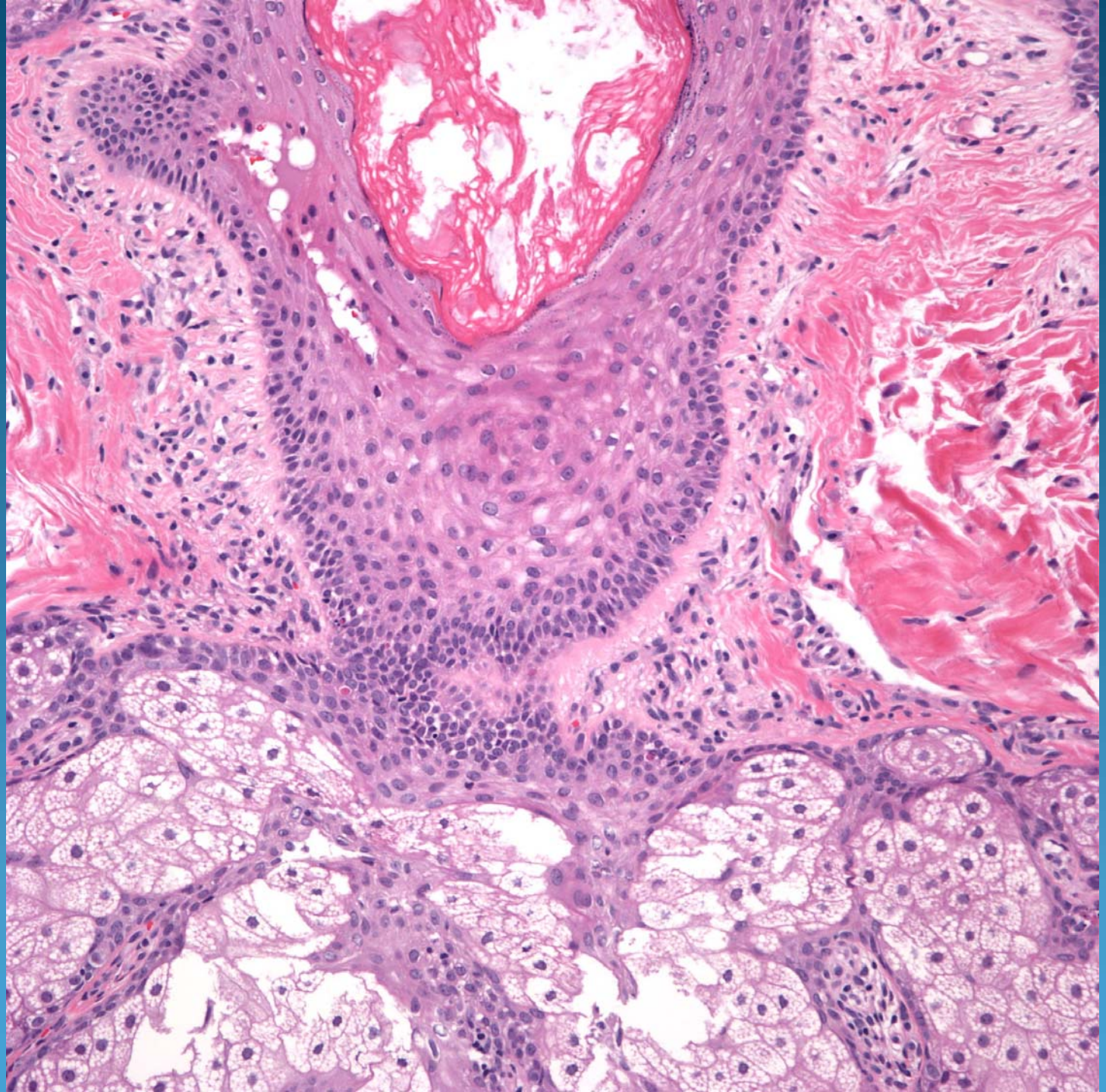

Trichofolliculoma

Pearls

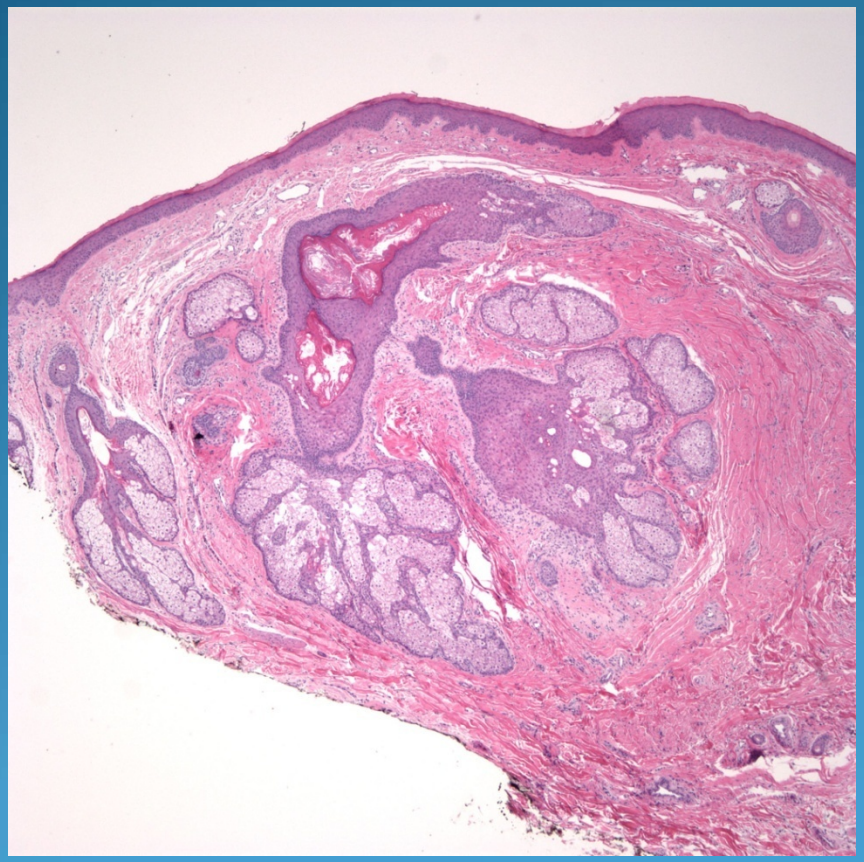

- Dilated hair follicle with several pilosebaceous units emptying into it
- Dermal circumscribed tumor which may show epidermal attachment
- Characteristic clinical presentation

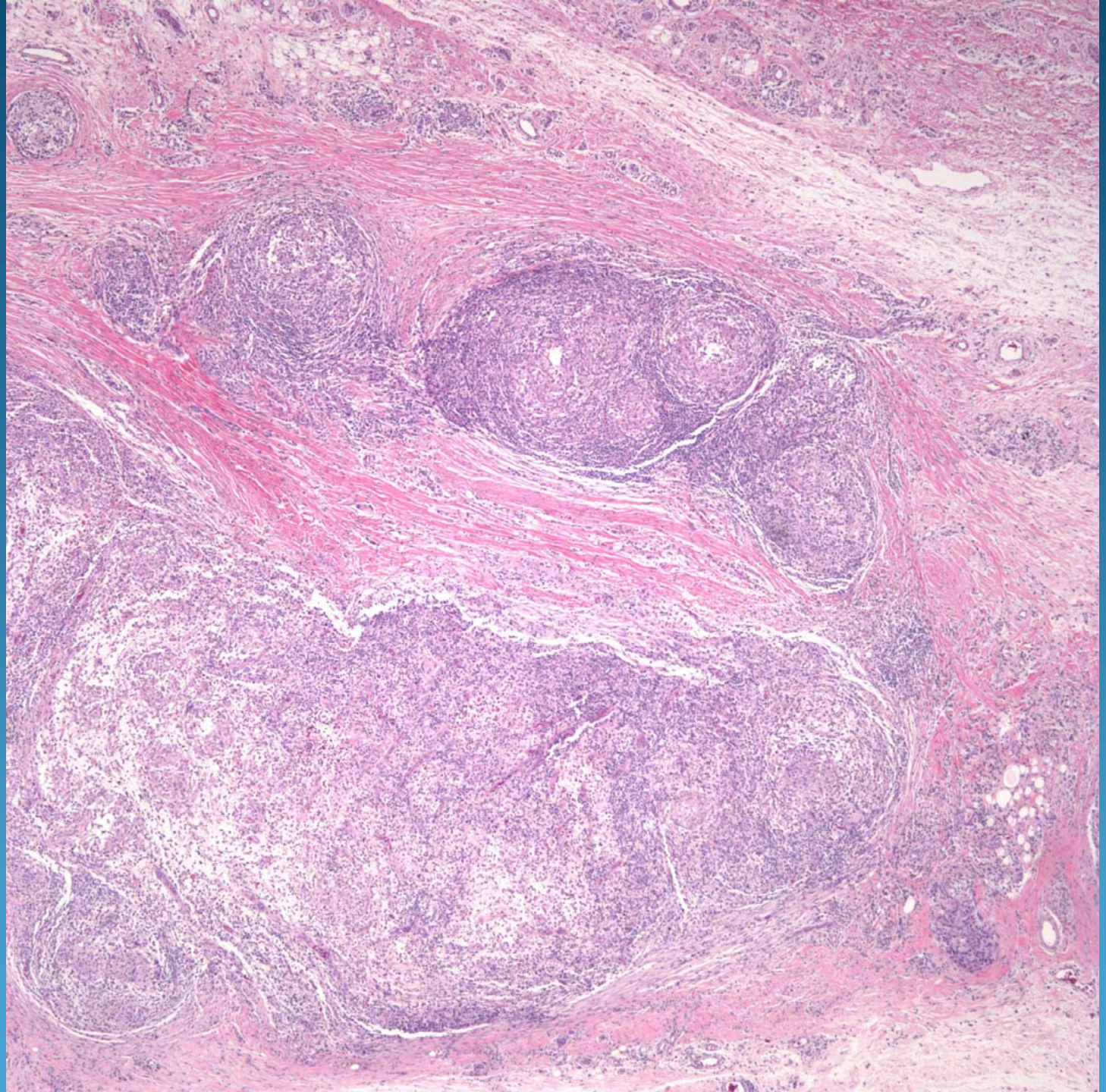

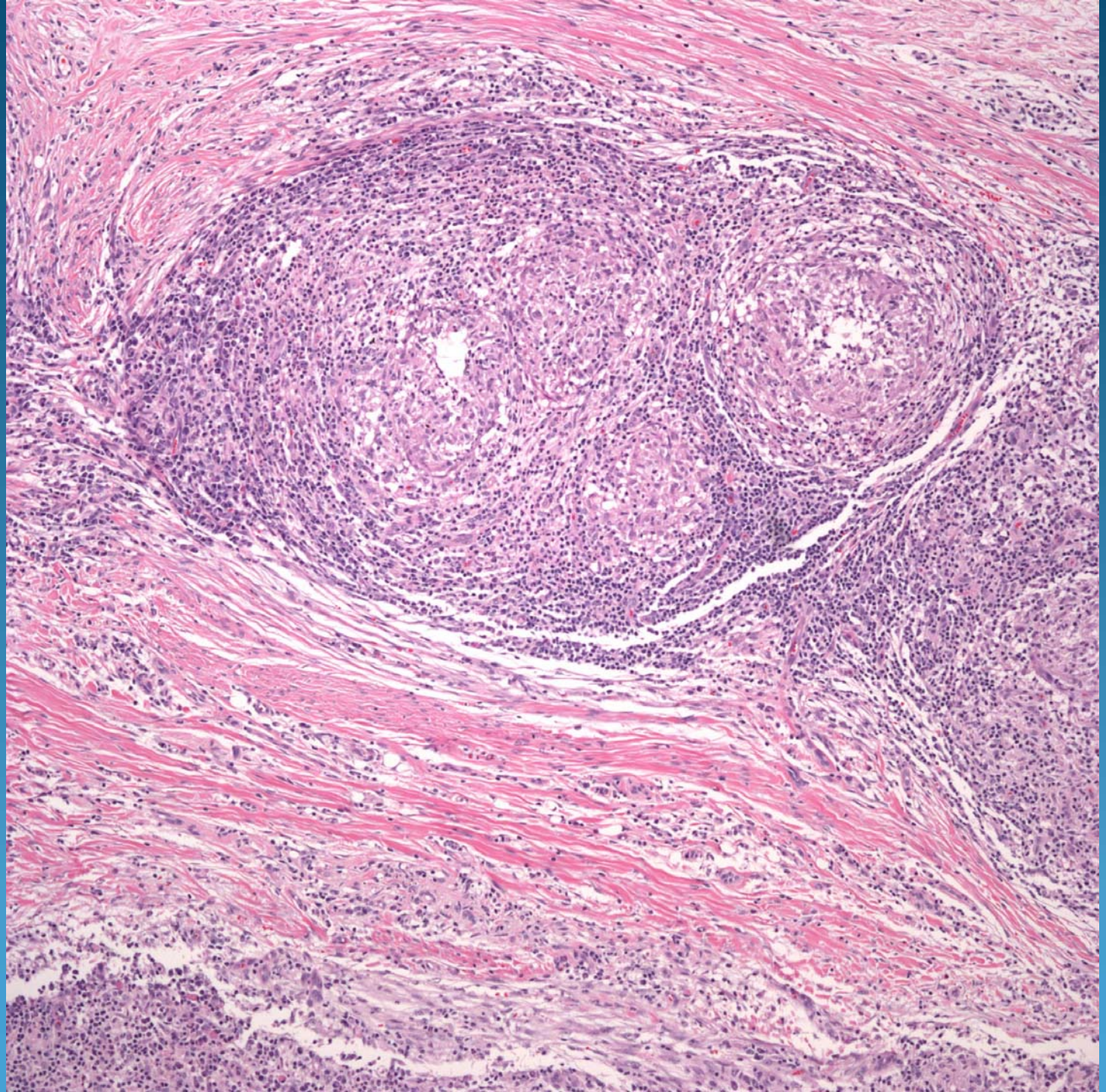

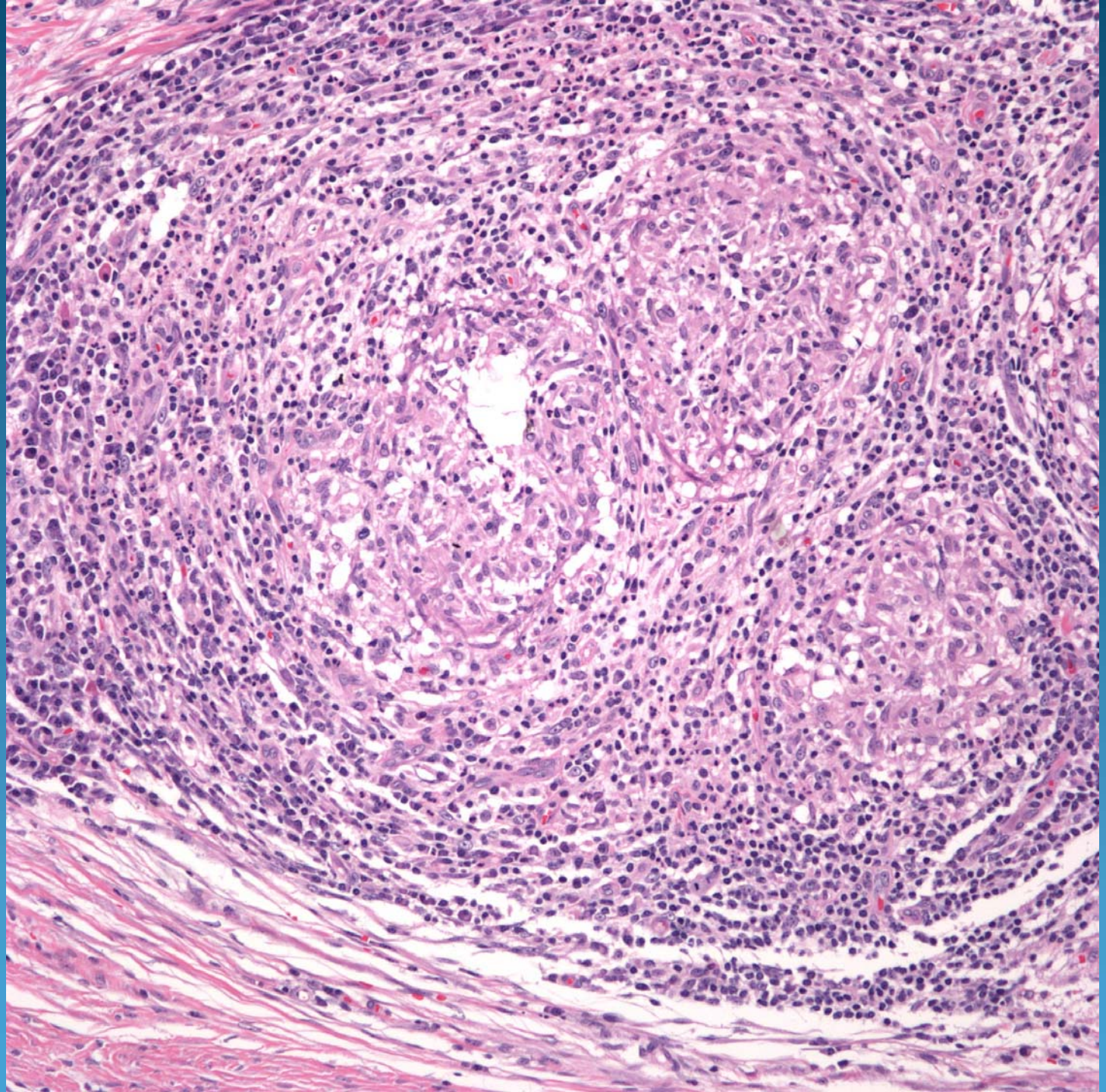

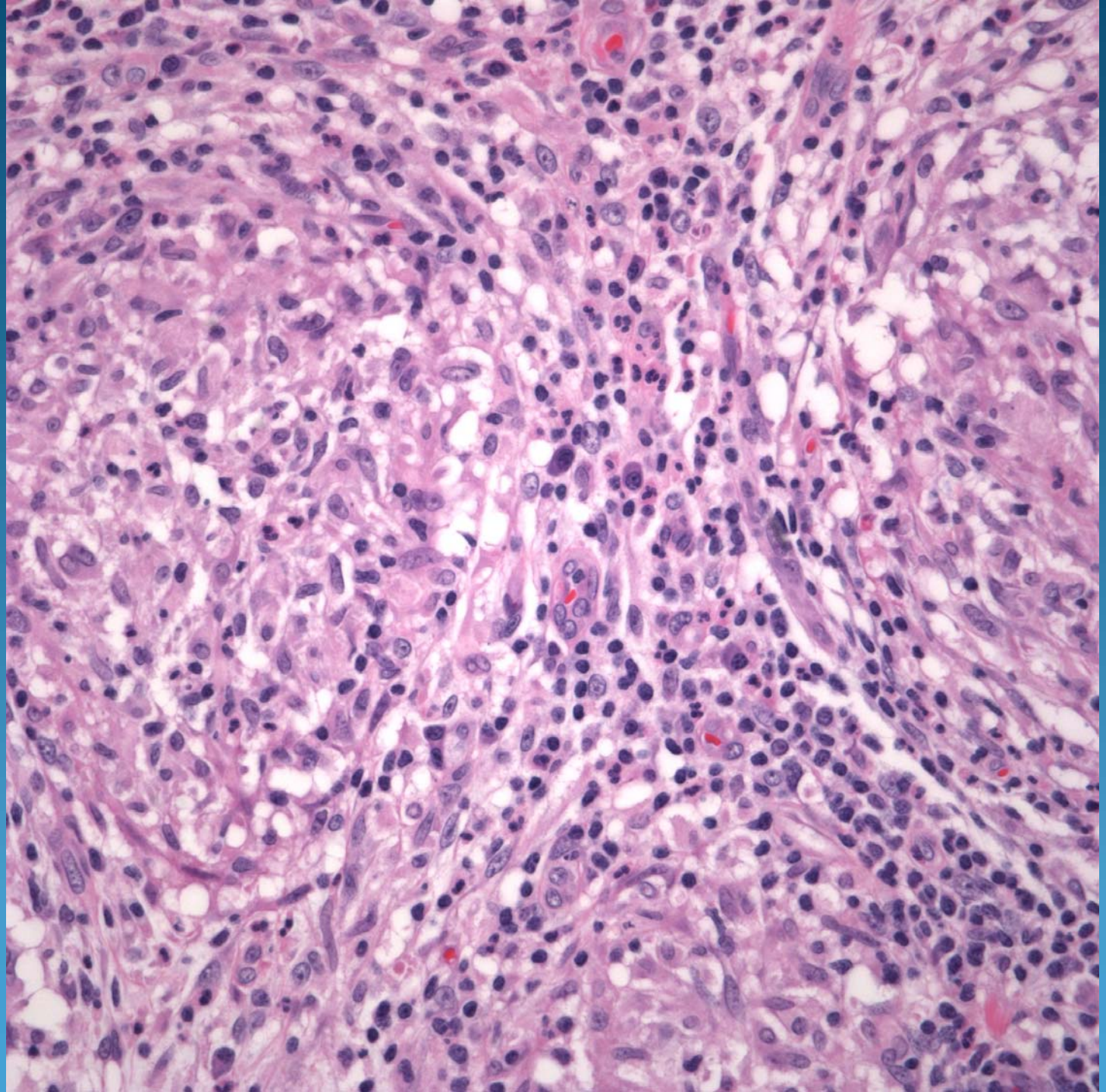

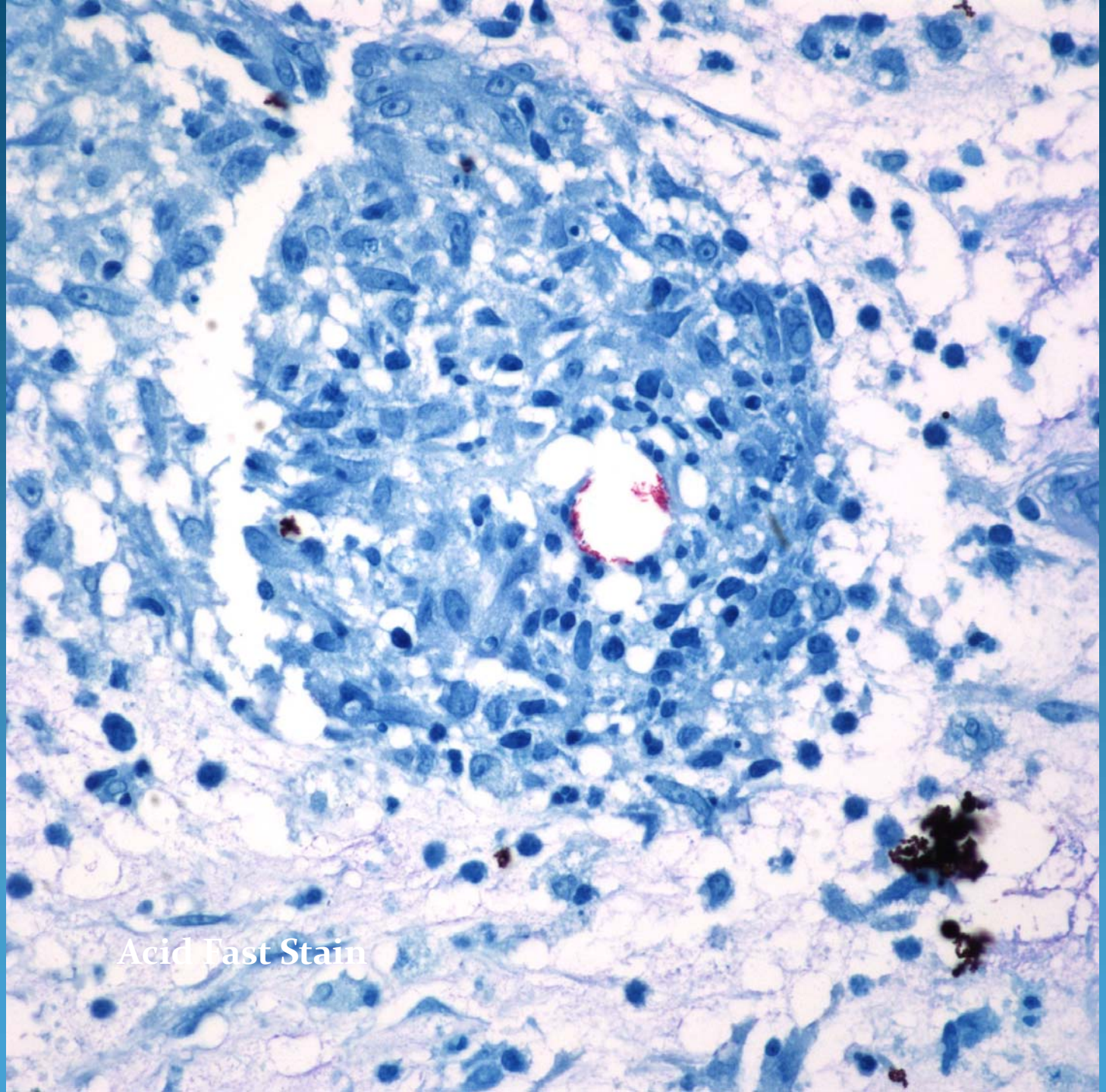
Acid Fast Stain

Cutaneous Tuberculosis

Pearls

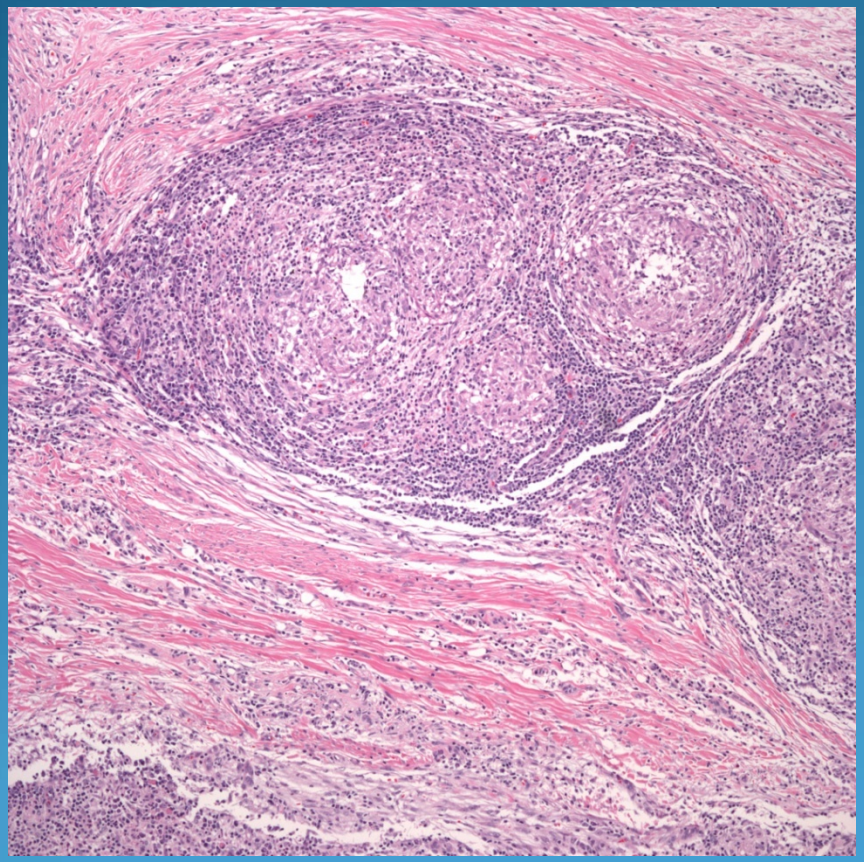

- Multiple suppurative and caseating granulomas with giant cells
- Use both Acid Fast and Fite stains to confirm
- Add PAS/Gram to rule out other micro-organisms
- Rule out leprosy

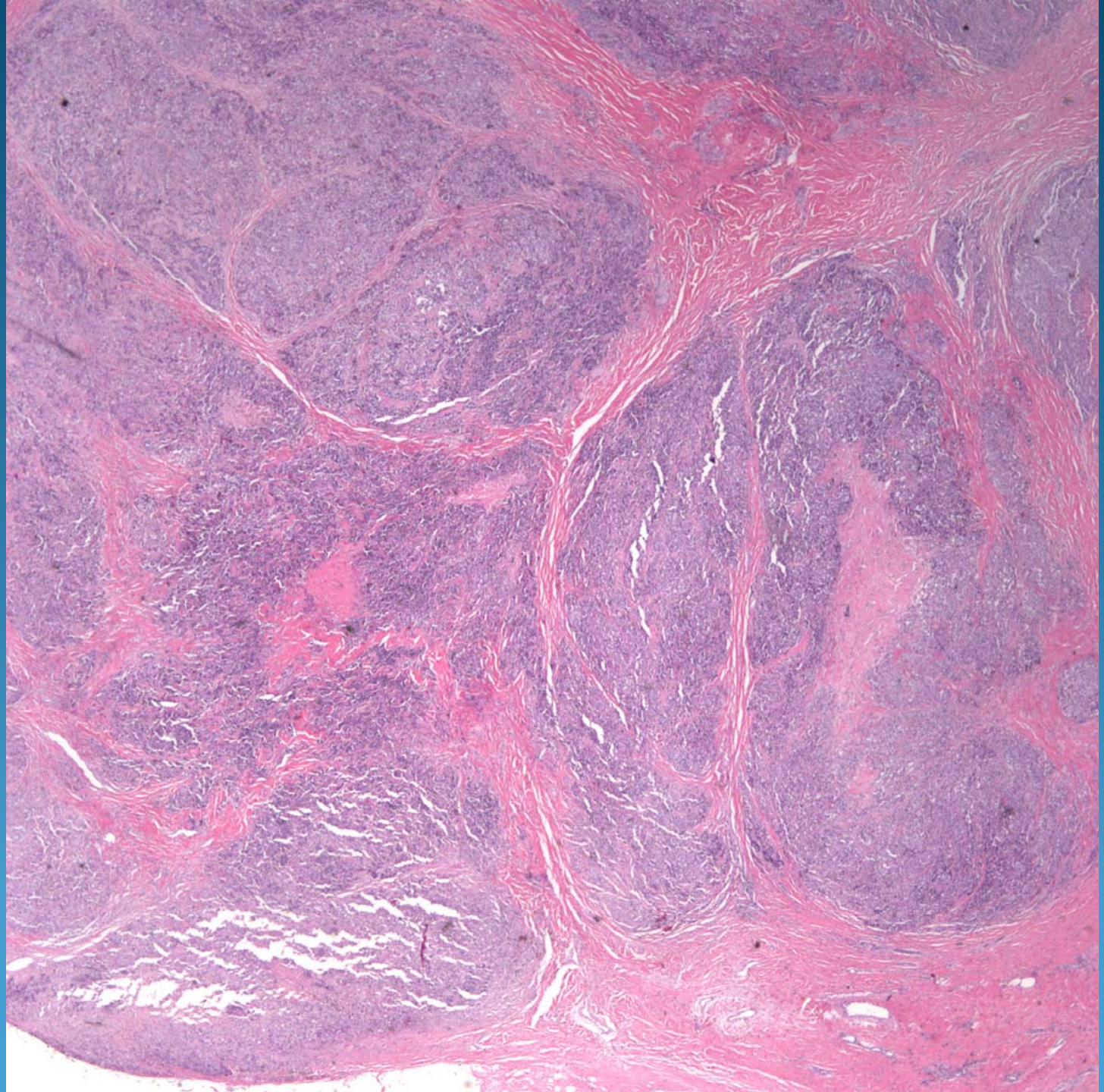

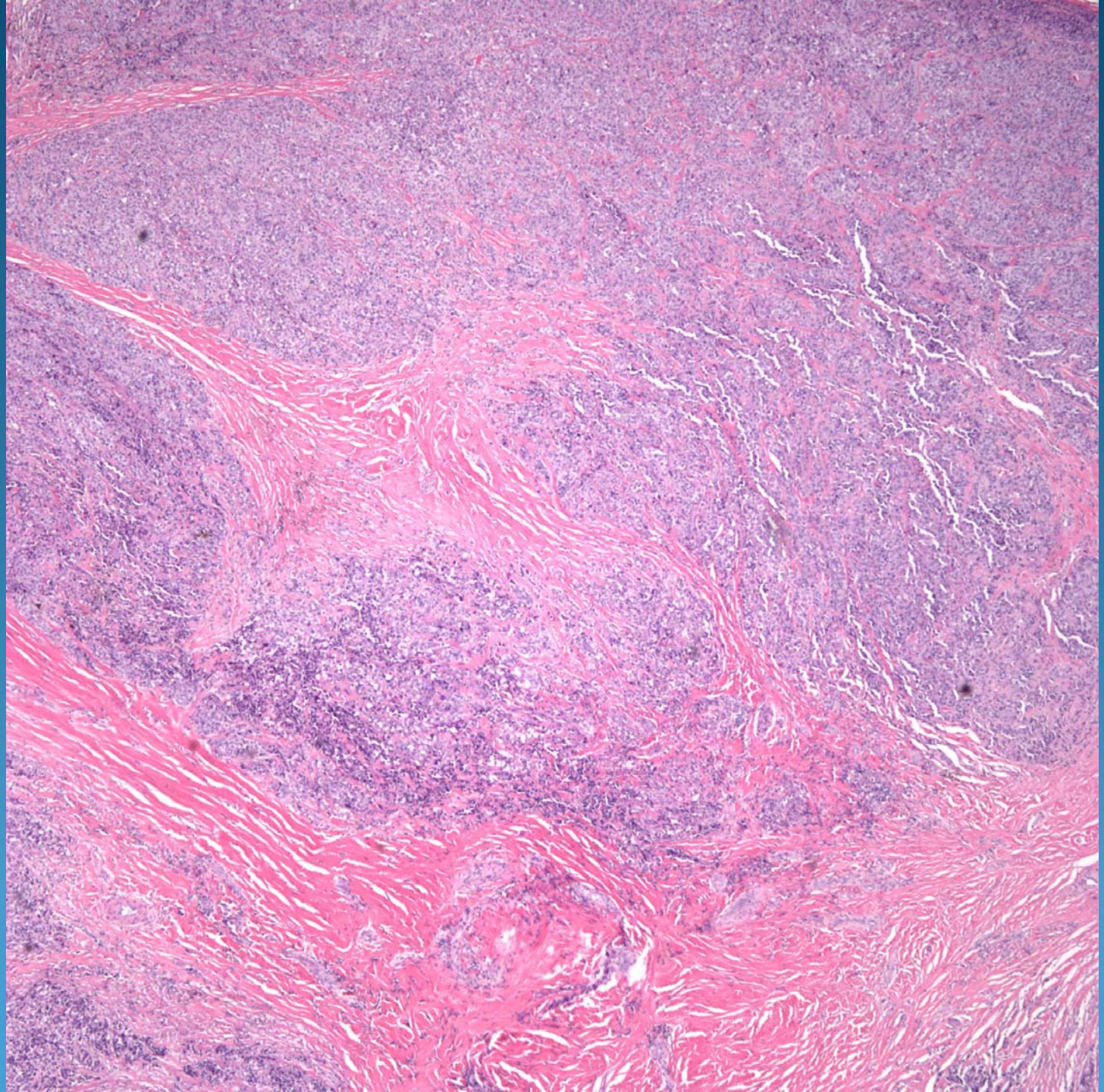

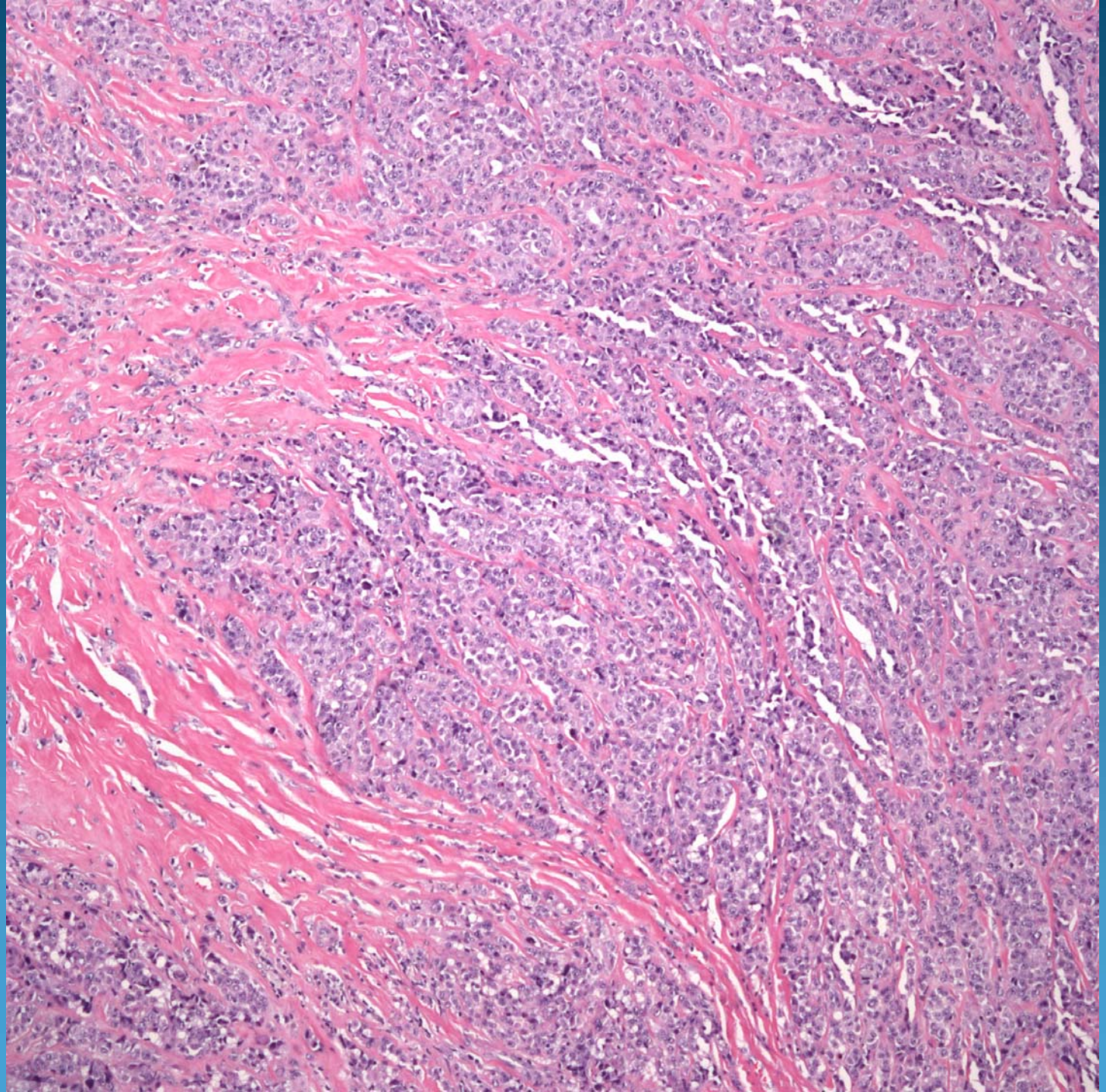

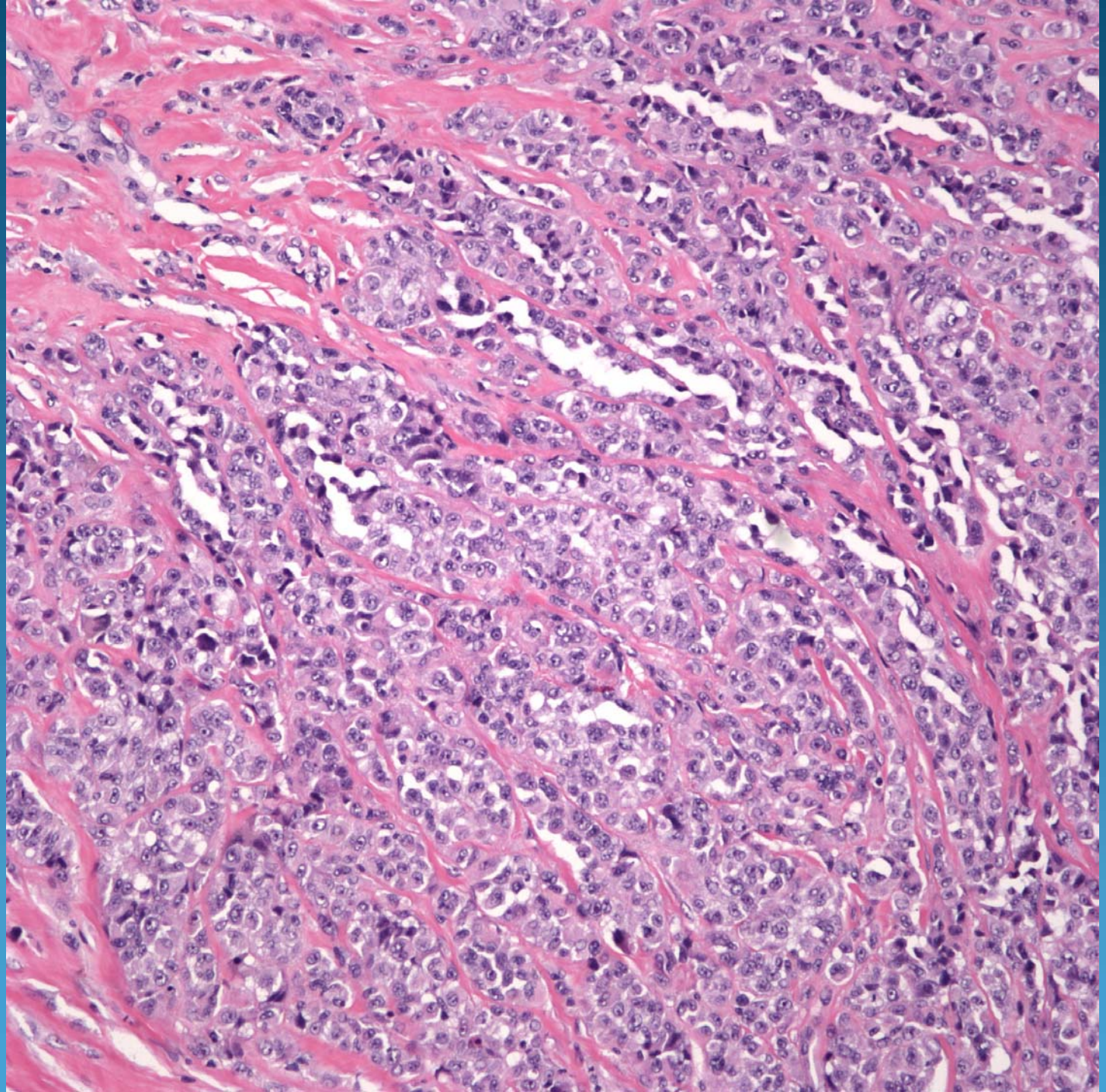

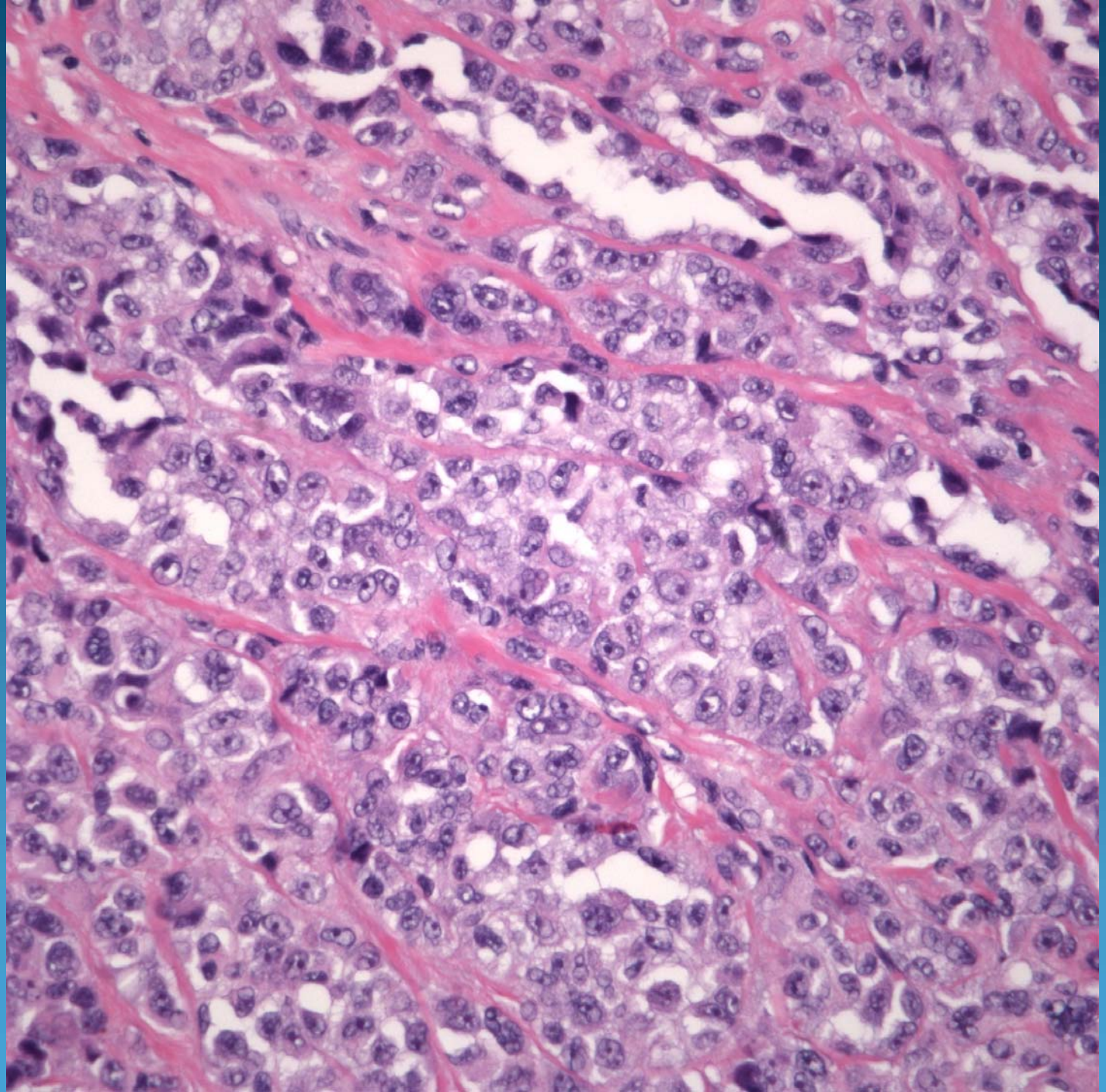

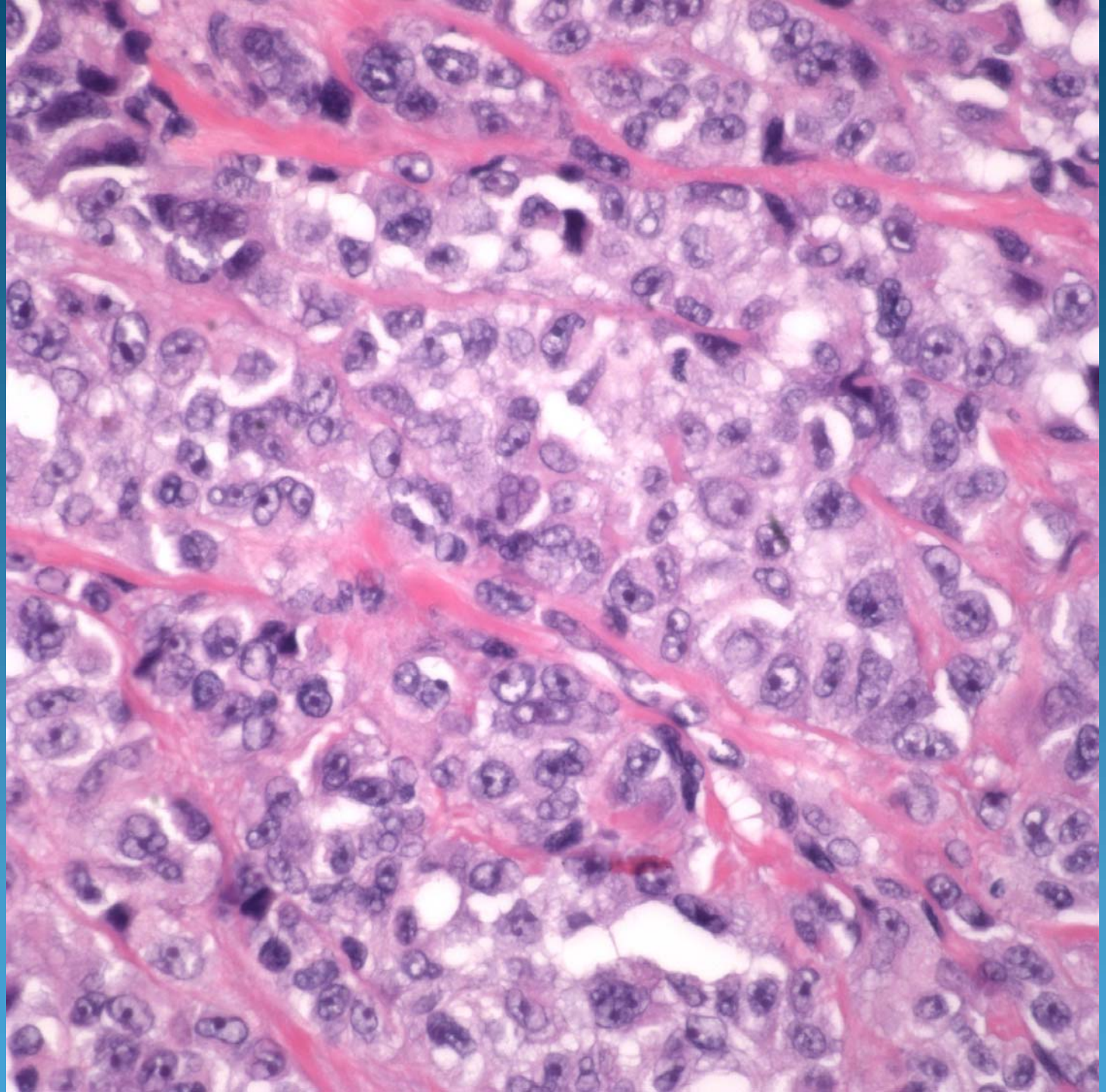

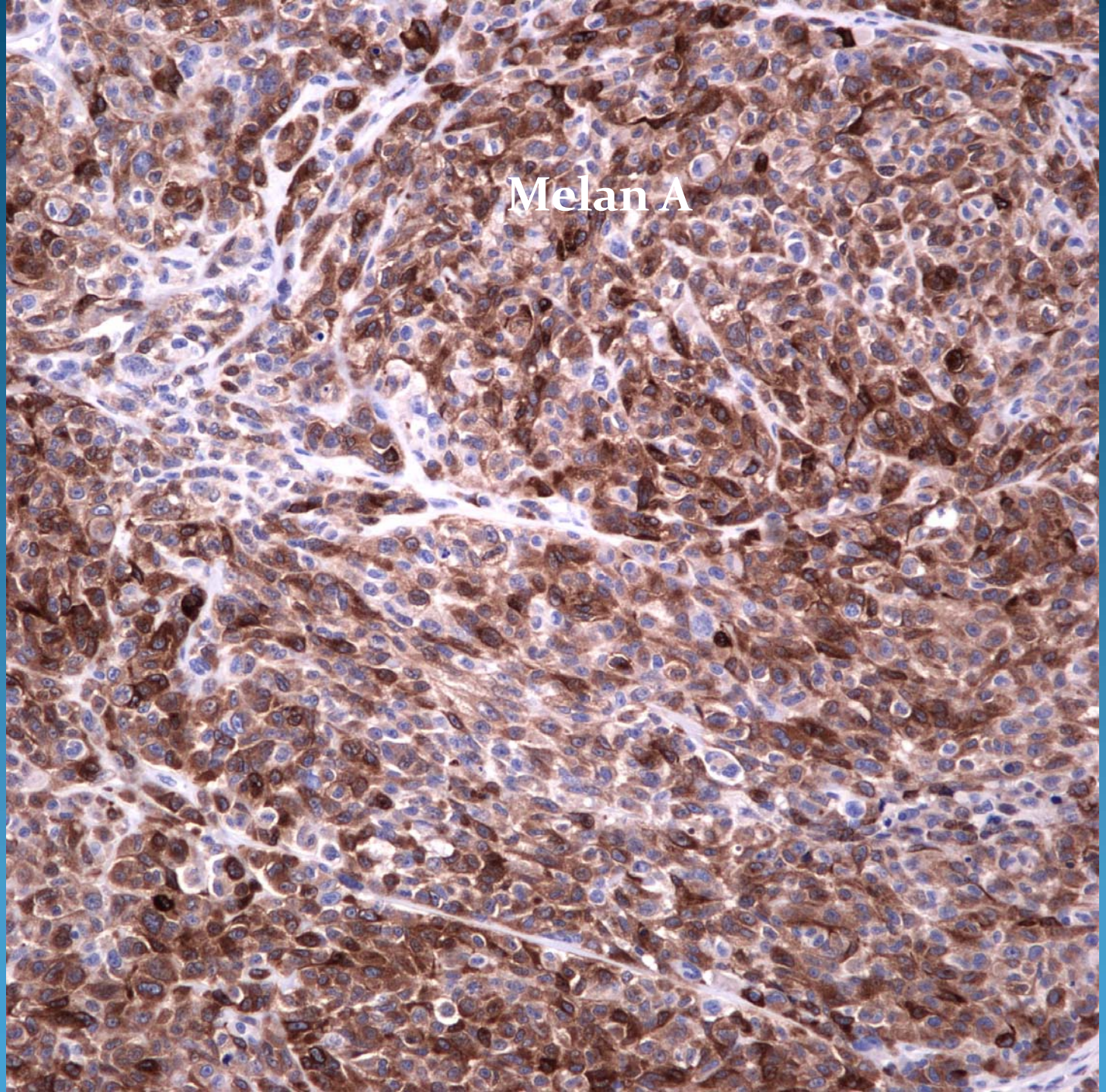
Melan A

Malignant Melanoma, Metastatic to Soft Tissue

Pearls

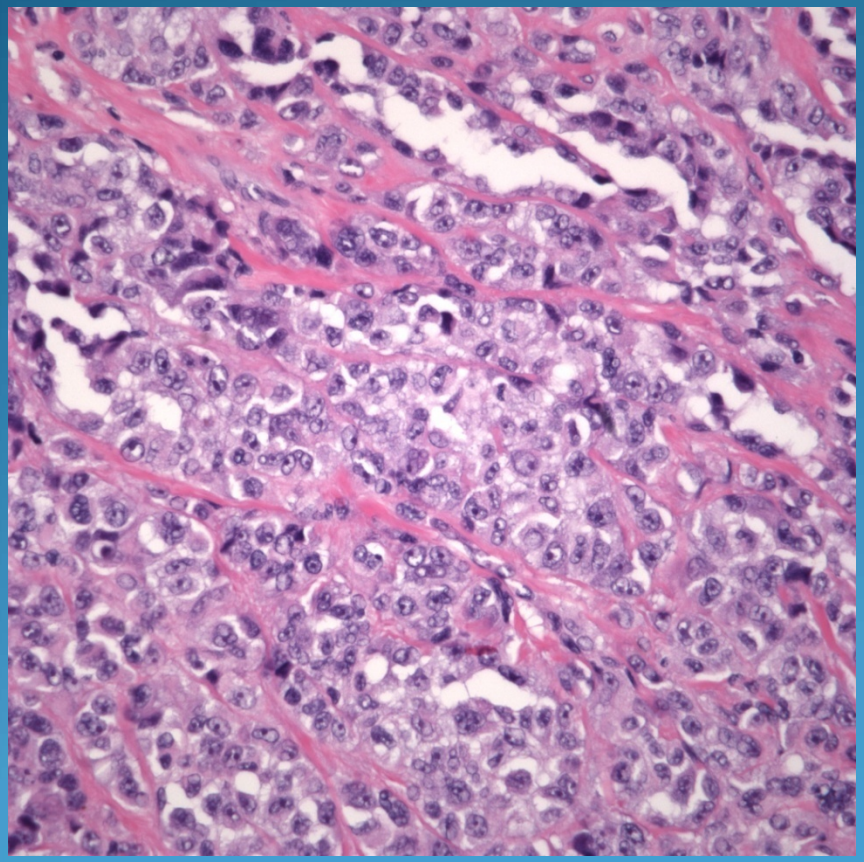

- Pleomorphic tumor which may show biphasic (epithelioid and spindled) appearance
- May not have melanin cytoplasmic pigment
- IHC to confirm
- Rule out metastatic carcinoma, sarcoma, and lymphoma